



Bilateral Optic Atrophy Following Methanol Poisoning: A Case Report

A. A. Onua^{1*}, I. C. Nwadiuto² and C. N. Pedro-Egbe¹

¹Department of Ophthalmology, University of Port Harcourt Teaching Hospital, P.M.B. 6173, Port Harcourt, Nigeria.

²Epidemiology Unit, Rivers State Ministry of Health, Port Harcourt, Nigeria.

Authors' contributions

This work was carried out in collaboration between all authors. All authors read and approved the final manuscript.

Article Information

DOI: 10.9734/BJMMR/2016/26645

Editor(s):

(1) Barbara Giambene, Eye Clinic, Department of Translational Surgery and Medicine, University of Firenze, Italy.

Reviewers:

(1) Pavel Urban, National Institute of Public Health, Czech Republic.

(2) Andrew G. Lee, The University of Iowa Hospitals and Clinics, Iowa City, IA, USA And The University of Texas Medical Branch, Galveston, TX, USA.

(3) Tarkan Mumcuoglu, Gulhane Military Medical Academy, Turkey.

(4) Venkataratnam Peram, N.T.R Health University (A.P) Sarojini Devi Eye Hospital, Hyderabad, India.

(5) Veysi Oner, Recep Tayyip Erdoğan University Medical School, Rize, Turkey.

(6) Srihari Atti, Sarojini Devi Eye Hospital & Regional Institute of Ophthalmology, Osmania Medical College(Govt.), Hyderabad, India.

Complete Peer review History: <http://www.sciencedomain.org/review-history/16635>

Case Report

Received 26th April 2016
Accepted 3rd October 2016
Published 22nd October 2016

ABSTRACT

Background: Methanol is an industrial chemical found in many products including antifreeze solutions, solvents and fuels. Most cases of methanol poisoning among humans occur following accidental ingestion, inhalation or dermal exposure. Humans may sometimes ingest methanol as an ethanol substitute or to inflict injuries on themselves. Multiple victim methanol poisonings can occur with illicit distillation or occult substitution of methanol for ethanol. The clinical diagnosis is made in the presence of toxic alcohol ingestion, early visual symptoms and unexplained metabolic acidosis.

Case Report: We report a case of methanol poisoning with bilateral optic atrophy in a 53-year old carpenter who presented to the ophthalmology clinic, University of Port Harcourt Teaching Hospital on 9th June 2015 on account of eight days history of sudden loss of vision in both eyes, following ingestion of alcohol with colleagues. Prior to presentation, he had good vision in both eyes. Clinical examination revealed visual acuity of hand motion in both eyes, widely dilated pupils with

*Corresponding author: E-mail: onuadr@gmail.com;

no reaction to light. Fundoscopy showed bilateral chronic optic atrophy. Based on the clinical and fundus photographic findings and the epidemiological report of methanol poisoning outbreak in Rivers State at this particular time from 30th May 2015 to 15th June 2015), a diagnosis of methanol poisoning was entertained. Patient was treated with folic acid, prednisolone and multivitamins.

Conclusion: Early recognition and treatment of methyl alcohol poisoning could prevent hazardous outcome. Late Presentation of our client worsened by poverty and ignorance led to optic neurotoxicity, with bilateral blindness. Practising ophthalmologist should have a high index of suspicion of alcohol related chronic optic neuropathy with blindness among chronic alcoholics.

Keywords: Methanol poisoning; optic neuropathy; Rivers State; Nigeria.

1. INTRODUCTION

Methanol is found in high concentration in industrial products such as automotive antifreeze and de-icing solutions, windshield wiper fluid, solvents, cleaners and fuels [1]. Most cases of poisoning among human populations occur following accidental ingestion, inhalation and dermal exposure [1]. Human beings may ingest toxic alcohols as an ethanol substitute or to inflict self-harm. Multiple victim methanol poisonings can occur with illicit distillation or occult substitution of methanol for ethanol [2].

The absorption of methanol following oral administration is rapid and peak methanol concentrations occur within 30-60 minutes in the plasma [3]. Methanol is oxidized by alcohol dehydrogenase to formaldehyde. The oxidation of formaldehyde to formic acid is facilitated by formaldehyde dehydrogenase. Formic acid is then converted by 10-formyl tetra-hydrofolate synthetase to carbon dioxide and water. There is a direct correlation between formic acid concentration and increased morbidity and mortality [3]. The acidosis observed in methanol poisoning appears to be caused directly or indirectly by formic acid production. Formic acid is the prime cause of ocular toxicity, though acidosis can increase toxicity further by enabling greater diffusion of formic acid into cells [3].

Clinically, methanol poisoning typically induces nausea, vomiting, abdominal pain, and central nervous system depression. Uncompensated metabolic acidosis develops and visual function becomes impaired, ranging from blurred vision and altered visual fields to complete blindness, neurologic sequelae, and even death [4]. Even though eye damage caused by methanol has been well described, the exact mechanism is not well understood. It is thought that vision loss may be due interruption of mitochondrial function in the optic nerve with resultant hyperemia, disc edema, and subsequent optic atrophy [5].

Another school of thought ascribes the visual dysfunction to optic nerve demyelination which results from destruction of the myelin sheath by formic acid. The major damage occurs at the retrolaminar optic nerve, with intra-axonal swelling and organelle destruction. Little or no change is seen in the retina [3]. Methanol also affects the basal ganglia; and hemorrhagic and non-hemorrhagic damage to the putamen are common problems in cases of severe intoxication. As a result of this damage, patients can develop parkinsonism or other dystonic/hypokinetic clinical pictures [5].

In the industrial setting, the inhalation of methanol fumes poses a health risk. However, unintentional methanol poisoning occurs under a variety of circumstances in several discrete populations, including children and persons with alcoholism where these individuals commonly consume methanol as a substitute for ethanol [6]. Prompt medical care is key to avoiding complications secondary to methanol intoxication. Multidisciplinary approach involving the nephrologist, ophthalmologist, neurologist and anaesthesiologist is essential. Supportive therapy is aimed at initiating airway management, correcting electrolyte disturbances, and providing adequate hydration [7]. Metabolic acidosis in methanol poisoning may necessitate the administration of bicarbonate and assisted ventilation. Bicarbonate may potentially reverse visual deficits as well as decrease the amount of active formic acid. Administration of antidotes such as ethanol or fomepizole delay methanol metabolism until the methanol is eliminated from the victim's system either naturally or via dialysis. Like methanol, ethanol is metabolized by alcohol dehydrogenase (ADH), but the enzyme's affinity for ethanol is 10-20 times higher than it is for methanol thus allowing the methanol to be metabolized slowly. Fomepizole is also metabolized by ADH; however, its use is limited because of high cost and lack of availability.[3] Hemodialysis can easily remove methanol and

formic acid from the system. The indications for hemodialysis include ingested methanol levels > 30mL, serum methanol levels > 20 mg/dL, observation of visual complications, and when there is no improvement in acidosis despite repeated sodium bicarbonate infusions [8].

The prognosis in methanol poisoning correlates with the amount of methanol consumed and the subsequent degree of metabolic acidosis as well as the time delay in medical intervention. The prognosis is further dependent on the amount of formic acid that has accumulated in the blood, with a direct correlation existing between the formic acid concentration and morbidity and mortality. Severe acidosis confers a poorer prognosis [9].

2. CASE REPORT

A 53-year old male carpenter presented to our clinic on 9th June 2015 on account of sudden loss of vision in both eyes, following consumption of a substance believed to be alcohol eight days earlier-(on Tuesday 2nd June, 2015). The patient was said to have consumed about 400 ml of illicit gin popularly called "ogogoro", with five of his friends in a remote area of Woji town, a suburb of Port Harcourt, Nigeria. All five friends took ill after consuming the said product and died within 5-24 hours. The index patient presented with the following symptoms: Included vomiting, headache, and diminution of vision, which occurred about 2-3 hours after consumption of the toxic product. Our patient received first aid at a private hospital in Woji area, before presenting at our Clinic. Prior to presentation, patient claimed he had good vision in both eyes. He is not a known diabetic or hypertensive patient. There is no history of glaucoma or blindness in the family. The patient admitted to drinking, on average 2 bottles of beer (about one litre) and 5-7 shots of local gin everyday. He is also a moderate cigarette smoker- smoking 8-10 sticks daily. The patient lives with his two wives and eight children in a two-room apartment in Woji Area of Port Harcourt. No family member or other families living in the same apartment complex has similar symptom.

Clinical examination revealed a middle aged man, conscious and alert, anxious-looking but in no obvious respiratory distress. He was well oriented in time, place and person. He was moderately pale, mildly icteric and mildly dehydrated. His blood pressure at presentation was 130/80 mmHg, pulse rate 82 beats per

minute and respiratory rate was 24 cycles/minute.

On ocular examination the visual acuity was Hand Movement (HM) in both eyes. The Pupils were widely dilated and there was no reaction to direct and consensual light reflexes in both eyes. Fundoscopy showed bilateral chronic optic atrophy and this was confirmed by fundus photography. Other ocular features were within normal limits for his age and sex. Laboratory investigations revealed normal complete blood count, fasting blood sugar, renal and hepatic functions. Arterial Blood Gas (ABG) analysis revealed metabolic acidosis with a pH of 7.16, pCO₂ -16.2 mmHg, HCO₃⁻ -6.1 meq/L, Na⁺-146 meq/L, K⁺- 4.1 meq/L and Cl⁻ -110.9 meq/L. The plasma methanol concentration was 25 mg/dl. In view of suspicion of illicit toxic alcohol ingestion, epidemiological report of methanol poisoning outbreak in Rivers State, acute visual loss, metabolic acidosis and fundus photographic findings, the clinical diagnosis of methanol poisoning was entertained which met the diagnostic criteria listed in Table 1. The patient refused hospital admission because of financial constraints. He was treated however with sodium bicarbonate, folic acid, hydroxocobalamin, prednisolone and multivitamin tablets and advised to eat a well-balanced diet and abstain from drinking alcoholic beverages and smoking cigarettes. Patient was however lost to follow up so we do not know if there was any improvement in vision.

3. DISCUSSION

In Nigeria in 2015, an outbreak of methanol poisoning was first reported in April in Ikale community, in Irele Local Government Area of Ondo State [10]. An outbreak of methanol poisoning was reported in Rivers state on the 30th of May but the first notification was received on the 3rd of June 2015 from Obio/Akpor Local Government Area (LGA) [11]. The index patient is resident in Woji area of Obio/Akpor LGA of Rivers State and presented to our clinic during the outbreak.

Methanol toxicity remains a common problem in many parts of the developing world, especially among members of the lower socioeconomic class [12]. In many parts of the developing world, methanol is often a component of "bootlegged alcohol," which is made in rural regions; because of its low cost, it is often consumed by members of lower socioeconomic class. The affected communities in Nigeria were sub-urban or rural

with majority of the affected persons being of low socio-economic status and persons with known alcoholism. Our index patient is a known alcoholic and the incidence occurred while drinking with five other friends after the day's work.

Methanol poisoning typically induces headache, nausea, vomiting, abdominal pain, and central nervous system depression, drowsiness which may progress to altered level of consciousness

and coma. Uncompensated metabolic acidosis develops and visual function becomes impaired, ranging from blurred vision and altered visual fields to complete blindness, neurologic sequelae, and even death [4]. Initial symptoms usually occur 12-24 hours after ingestion, but the incubation period may vary with the volume of methanol ingested [3]. Our index patient had headache, loose stool, and difficulty hearing and speaking, accompanied by swelling of the tongue and sudden loss of sight.

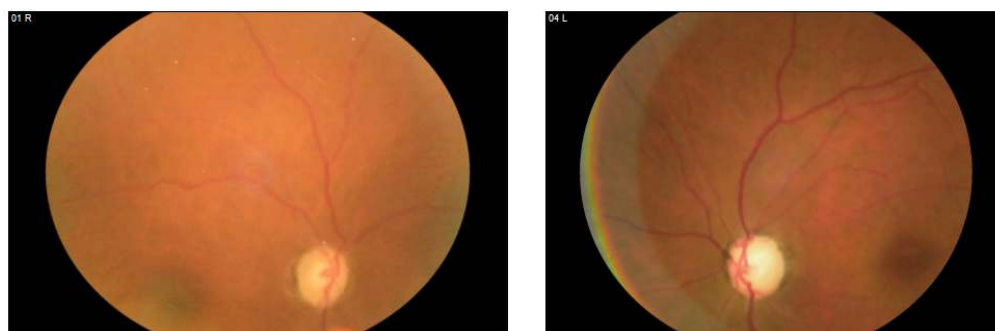


Fig. 1. Photomicrograph of bilateral optic atrophy, worse in the left eye

Table 1. Criteria of diagnosing methanol toxicity [12]

1.	Documented plasma methanol concentration >20 mg/dL (>200 mg/L)
2.	Documented recent history of ingesting toxic amounts of methanol and osmolal gap >10 mOsm/kg
3.	History or strong clinical suspicion of methanol poisoning with at least two of the following criteria:
	a. Severe metabolic acidosis i.e. Arterial pH <7.3
	b. Serum bicarbonate <20 meq/L
	c. Osmolal gap >10 mOsm/kg (Any of the 3)

Table 2. Comparison between diagnostic criteria of methanol poisoning by Nand et al. [12] and observed parameter in the index patient

	Diagnostic criteria of methanol poisoning by Nand et al. [12]	Observed parameter in the index patient
1.	History or strong clinical suspicion of methanol poisoning with at least two of the following criteria	Documented history of methanol poisoning in Port Harcourt, Rivers State, Nigeria during the period the index patient reported to our clinic (30 th May to 15 th June 2015) [11]
2.	Documented history of ingested toxic amount of methanol	Evidence of consumption of "illicit alcohol" termed "ogogoro" from the patient's History. Patient's friends who partook in the illicit alcohol consumption died within 5-24 hours
3.	Severe Metabolic acidosis pH<7.3	Severe Metabolic acidosis pH=7.16
4.	Serum bicarbonate< 20 meq/L	Serum bicarbonate= 6.1 meq/L
5.	Documented Plasma methanol concentration> 20 mg/dl	Plasma methanol concentration of 25 mg/dl

Methanol poisoning carries a high mortality rate especially among rural dwellers with lack of infrastructure and tertiary care facilities [4]. In Ondo State, Nigeria, 25 people died from methanol poisoning and in Rivers State 71 deaths were reported. Out of 82 reported cases in Rivers State, most of the victims lost their lives within 15 days of consumption of the methanol (Case Fatality Rate (CFR) =86.5%) [10,11]. The lethal dose of methanol is 30-50 ml; the smallest reported dose to cause death is 15 ml of 40% of methyl alcohol. Permanent visual loss may occur with doses as low as 10 ml [3]. The symptoms are usually non-specific except for visual disturbances, which include blurring of vision, central scotoma and blindness. Ocular examination may reveal mydriasis, amaurosis, retinal edema, hyperemia papilledema and optic atrophy. Our patient had most of these symptoms.

When compared to Nand et al diagnostic criteria, our index patient met the diagnosis of methanol poisoning (Table 2): Laboratory evidence of metabolic acidosis, decreased bicarbonate blood level with methyl alcohol level > 20 mg/dl confirmed the diagnosis of the methyl alcohol poisoning using the criteria listed in Table 1.

Imaging studies of the brain such as CT and MRI usually show typical CNS toxicity characterized by bilateral putaminal hemorrhagic necrosis due to selective vulnerability of these regions to methanol toxicity [8]. In our patient, no imaging studies were done (even though it was requested for) because of financial constraints but based on the laboratory evidence, we were able to make a diagnosis of methanol poisoning.

Rapid decision making, early and aggressive management is crucial to prevent an untoward outcome in methanol toxicity. The first treatment is to secure and maintain the airway, breathing and circulation followed by an intravenous injection (bolus) of sodium bicarbonate 1 - 2 mg/kg for patients with pH below 7.3 and then a maintenance infusion till arterial pH rises to or is above 7.35 [8]. Treatment with ADH inhibitors, fomepizole (4-methyl pyrazole) or ethanol is initiated earlier to delay the metabolism of methanol to its' toxic metabolite 'formate', and to prevent its accumulation and toxicity. The loading dose of Fomepizole is 15 mg/kg intravenously followed by 10 mg/kg every 12 hours; ethanol is administered intravenously or orally to maintain the blood level of 100 mg/dl [9].

4. CONCLUSION

Practising ophthalmologist should have a high index of suspicion of alcohol related chronic optic neuropathy with blindness among chronic alcoholics. The early diagnosis of methanol poisoning aims at timely initiation of treatment including ADH inhibitors to prevent formic acid accumulation with its' resultant adverse effects – permanent blindness, coma and death. The late presentation of our case was worsened by ignorance and poverty thus leading to the typical clinico-pathological manifestations of severe metabolic acidosis and typical optic neurotoxicity. Prevention of methanol poisoning can be achieved through effective health education of the populace and enactment of enabling legislation prohibiting illegal distillation of alcoholic beverages.

CONSENT

Patient gave oral informed consent for the case report and accompanying images to be published.

ETHICAL APPROVAL

Ethical approval was obtained from the University of Port Harcourt Teaching Hospital Ethics Committee.

COMPETING INTERESTS

Authors have declared that no competing interests exist.

REFERENCES

1. Givens M, Kalbfleisch K, Bryson S. Comparison of methanol exposure routes reported to Texas poison control centers. *West J Emerg Med.* 2008;9(3):150–153.
2. Kumar SS, Boopathy KS, Bhaskar ME. Methanol poisoning – A Chennai experience. *J Assoc Physicians India.* 2003;51:425-426.
3. Barceloux DG, Bond GR, Krenzelok EP, et al. American academy of clinical toxicology practice guidelines on the treatment of methanol poisoning. *J Toxicol Clin Toxicol.* 2002;40:415-446.
4. Fontenot AP, Pelak VS. Development of neurologic symptoms in a 26-year-old woman following recovery from methanol intoxication. *Chest.* 2002;122(4):1436–1439.

5. Shukla M, Shiroh I, Saleem A. Intravenous methylprednisolone could salvage vision in methyl alcohol poisoning. Indian J Ophthalmol. 2006;54:68-69.
6. Fein DM, Sue YJ. Methanol ingestion. Pediatr Rev. 2011;32(12):549–550.
7. Kruse JA. Methanol and ethylene glycol intoxication. Crit Care Clin. 2012;28(4): 661–711.
8. Trivedi TH, Yeolekar ME, Shejale SB. Methanol poisoning in medical intensive care unit. J Assoc Physicians India. 2001;49:257-258.
9. Shah S, Pandey V, Thakore N, Mehta I. Study of 63 cases of methyl alcohol poisoning (Hooch Tragedy in Ahmedabad). J Assoc Physicians India. 2012;60:34-36. Available:<http://en.wikipedia.org/wiki/Irele> (Assessed on 19/3/16)
10. Available:<http://en.wikipedia.org/wiki/Irele> (Assessed on 19/3/16)
11. Available:www.globalhealthnow.org (Assessed on 26/4/16)
12. Nand L, Chander S, Kashyap R, Gupta D, Jhobta A. Methyl alcohol poisoning: A manifestation of typical toxicity and outcome. Journal of the Association of Physicians of India. 2014;62:756-759.

© 2016 Onua et al.; This is an Open Access article distributed under the terms of the Creative Commons Attribution License (<http://creativecommons.org/licenses/by/4.0>), which permits unrestricted use, distribution, and reproduction in any medium, provided the original work is properly cited.

Peer-review history:
The peer review history for this paper can be accessed here:
<http://sciencedomain.org/review-history/16635>