



Advanced Physiotherapy of Supracondylar Femur Fracture with Implant *In situ*: A Case Report

Shraddha Kochar^{a#}, Mitushi Deshmukh^{a*†} and Neha Chitale^{a‡}

^a *Department of Musculoskeletal Physiotherapy, Ravi Nair College of Physiotherapy, Datta Meghe Institute of Medical Sciences, Sawangi, Wardha, India.*

Authors' contributions

This work was carried out in collaboration among all authors. All authors read and approved the final manuscript.

Article Information

DOI: 10.9734/JPRI/2021/v33i54B33791

Editor(s):

(1) Dr. Rafik Karaman, Al-Quds University, Palestine.

Reviewers:

(1) Vikash Raj, All India Institute of Medical Sciences-Deoghar, India.

(2) Gerardo Terán Méndez, CECYT 2, Instituto Politécnico Nacional, Mexico.

Complete Peer review History, details of the editor(s), Reviewers and Additional Reviewers are available here:

<https://www.sdiarticle5.com/review-history/76974>

Case Study

Received 10 September 2021

Accepted 13 November 2021

Published 13 December 2021

ABSTRACT

Patient main concerns were restriction of movements of right knee and pus discharge from wound over right knee. In this case, the main clinical findings were a substantial loss in range of motion at right knee joints. There was also fixed flexion deformity seen over right knee. Diagnosis of the case was non united operated infected case of supracondylar femur fracture right side with implant in situ. In these types of circumstances, therapeutic approaches have been demonstrated to be useful. A 35-year-old male visited the orthopaedics who referred department of physiotherapy with complaints of restriction of movement of right knee and pus discharge from wound over right knee. Patient was examine in standing and supine position .On inspection, patient keeps right hip in flexion, knee in flexion patella pointing upwards and foot in equinus. According to the research, starting weight-bearing too soon can lead to failure of implant and mal-union. Supracondylar femoral fracture is a challenging condition to deal with and is associated with many secondary complications. An important role is played by physiotherapist in rehabilitation and supracondylar femur fracture management.

[#]BPT Student;

[†]Assistant Professor;

[‡]Resident;

*Corresponding author: E-mail: mitushideshmukh11@gmail.com;

Keywords: *Supracondylar femur fracture; implant in situ; distal femur fracture; flexed fix deformity; physiotherapy.*

1. INTRODUCTION

Road traffic crashes and falls have become more frequent as the transportation and construction industries increase. These are also raising the severity and frequency of Supracondylar femur fractures [1]. A fracture of the intersection between the diaphyseal cortical bone and the femoral condyle cancellous bone is known as the distal femoral metaphysis, is described as a supracondylar fracture of the femur [1]. Supracondylar femur fractures are a challenging issue to deal with [2]. Unbalanced stresses from the adductor and gastrocnemius muscles acting directly on the metaphyseal fragment can create a varus and flexion deformity [2]. The prevalence rate is 0.4 percent, with a varying epidemiology: The frequency peak for males in their 30s is found in a conventional bimodal distribution and a frequency peak for elderly women; however, it is as of now mainly found in women and the elderly, with more than half of the patients being above 65 [3]. Fractures of the supracondylar femur are frequently associated with substantial comminution and soft tissue damage [4]. These are major injuries that can be difficult to treat operatively [5]. High-energy and low-energy distal femoral fractures have been categorized [6]. High-energy trauma, like the one caused by car accidents, may result in open injuries with significant comminution of the condyles and metaphysis [6]. Low-energy trauma is tied to the elderly and people with severe osteoporosis [6]. Most distal femur fractures were effectively treated in the early 1960s, with fracture bracing and traction yielding satisfactory performance in 67 percent to 90 percent of patients [5]. The pendulum shifted from conservative management to surgical stabilisation of these injuries with the introduction of novel surgical procedures and implants [5].

The distal femur is divided into two areas: a supracondylar area between the meta-diaphyseal junction and the condyles, and an intercondylar region between the condyles and the articular surfaces [5]. The treatment of supracondylar femur fractures with condylar buttress plates was historically common [4]. Femur Supracondylar Fractures are classified as either flexing or extending, with the former being more common [1]. Regardless of the type of fracture, the adductor muscle, gastrocnemius, quadriceps femoris, and hamstrings contract and

stretch, causing the broken end to be removed [1]. The broken end, however, is likely to cause injury to the popliteal vascular due to the anatomical position of the vascular, such as traction, contusion, and puncture [1].

2. PATIENT INFORMATION

A 35-year-old male visited the orthopaedics who referred physiotherapy department who apparently alright before 2 years and then had a Road Traffic Accident on December 2018 sustaining injury over right knee for which he was operated at AVBRH. He also complained of restriction of movement of right knee and had Fixed Flexion Deformity of 20 degree in right knee since 2 years. Healing wound of 1x1 cm size was present over dorsal aspect of right knee. On and off type yellowish pus discharge was present from the wound since 8 months and the wound was developed after screw removal because patient had not taken medications at home. He also had history of screw impingement 1 year back which was removed in AVBRH only and had no history of head injury, ENT bleed, LOC and Seizures.

He visited orthopaedic surgeon where X-ray was performed and he was diagnosed with Supracondylar femur fracture right side with implant in situ, antibiotics were given to the patient after surgery, drugs, I/V fluids and other medications were also given, also the position of the limb was elevated and the bed position was neutral. Postoperatively, the patient's main symptoms were pain and swelling around the right knee, as well as decreased joint range of motion (ROM) and difficulties completing daily activities. The operation was under all aseptic precautions with patient position in supine, the painting and draping of right lower limb was done and 1cm Curvilinear incision was taken over dorsolateral aspect of lower thigh, soft tissue dissection was done, the screw was exposed and then removed, the fracture site was exposed with guidance of c arm and PRP infiltrated at fracture site was under guidance of c arm by 18 G needle, thorough wash was given with betadine and normal saline. The closure and sterile dressing was done. There was no presence of any co-morbidities.

3. CLINICAL FINDINGS

The patient was examined in standing and supine position. On inspection, patient keeps

right hip in flexion, knee in flexion, patella pointing upwards and foot in equinus. Presence of on and off pus discharge from wound which is present since 8 months. On palpation it was found that his local temperature is not raised,

tenderness was present over dorsal aspect of lower thigh, palpable implant (plate) present over lateral side of knee, knee flexion range of motion was restricted, active ankle and toe movement and the sensations were intact.

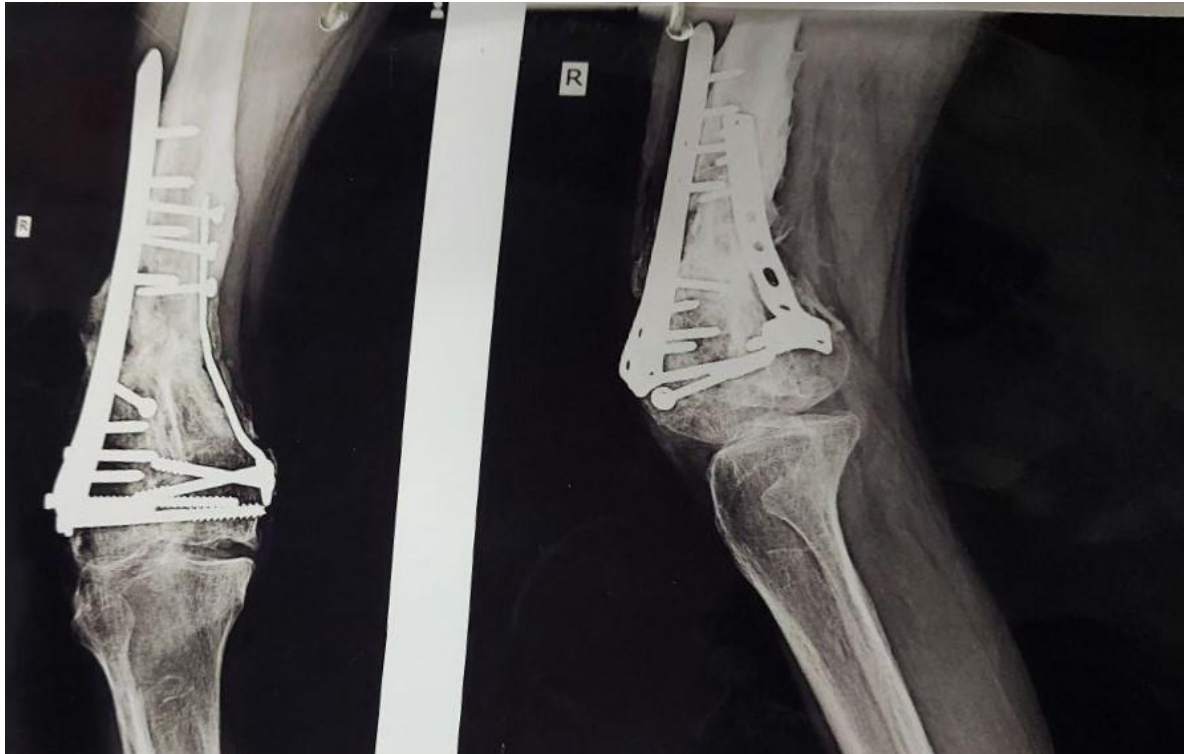

Fig. 1. Showing X-ray of patient's right knee

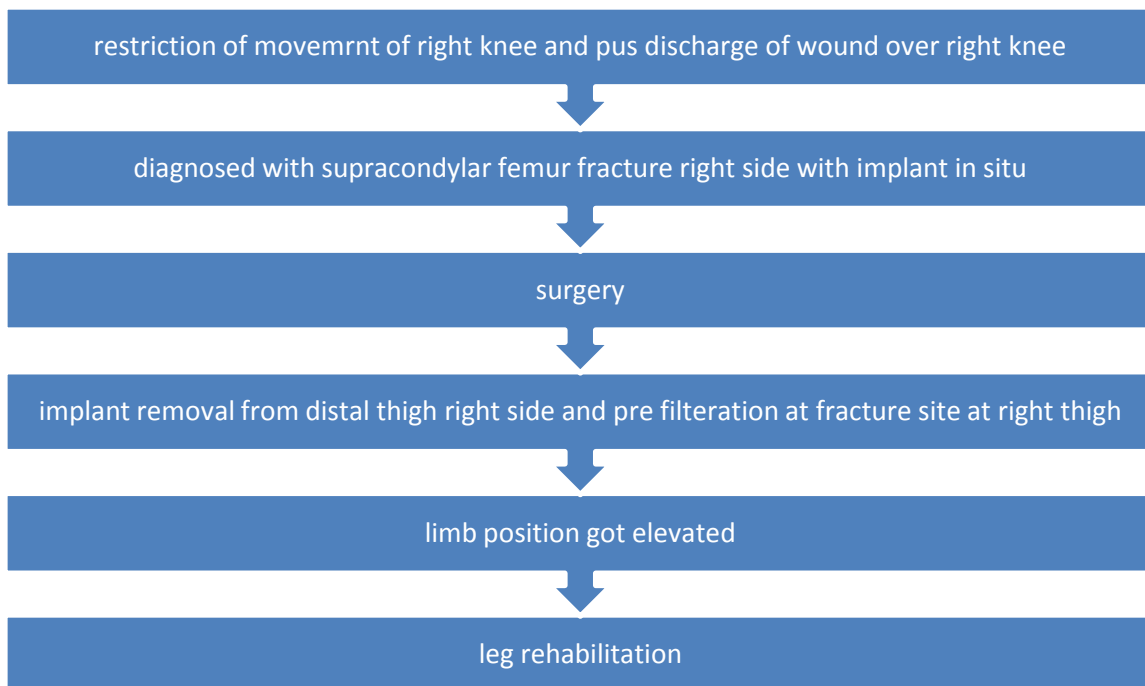


Fig. 2. Flow chart showing the progression

Chart 1. Timeline

Date of injury (RTA)	December 2018
Referral to hospital	28/09/2021
Date of operation	30/09/2021

Table 1. On the first day of rehabilitation, the ROM of the joint assessed

Joint	Active ROM (in degrees)	Passive ROM (in degrees)
Knee Joint	10-15	0-15

LEFS: Pre minimum score – 23/80

3.1 Diagnostic Assessment

Patient is 35 years old and met with a RTA and visited AVBRH immediately, the results were supracondylar fracture of femur of right side with implant in situ. Post-surgery patient was advised physiotherapy.

keeping the heel in contact with the bed and perform hip-knee flexion. Strengthening of unaffected side with 1kg weight cuff was started along with upper limb strengthening with weight cuff. Non-weight bearing ambulation was initiated in this phase.

3.2 Therapeutic Intervention

3.2.3 Phase 3 (5-8 weeks)

3.2.1 Phase 1 (0-2 weeks)

The aim of phase 3 was to make the person independent. During this phase, the patient moved from non-weight bearing to partial weight bearing to full weight bearing walking. To progress from non-weight bearing to full weight bearing walking strengthening exercises were given to the unaffected extremity. Straight leg raise and hip abduction exercises were given.

The primary goal in first phase was educating the patient and preventing secondary complications and maintaining the strength of the lower limb muscles. Secondary complications include deep vein thrombosis and pressure sores. To prevent secondary complications ankle toe movements were given, in which the patient was asked to perform ankle dorsiflexion and plantarflexion and repeat for 10 times every 2 hourly.

The patient still maintained fixed flexion deformity, for that deformity continues passive movement was given for 30 minutes.

To maintain the strength of lower limb muscles isometric exercises for quadriceps, hamstrings and glutei were given for 10 repetition with 10 seconds hold.

3.2.4 Follow-up and Outcomes

LEFS: Post minimum score – 47/80

3.2.2 Phase 2(3-4 weeks)

4. DISCUSSION

The goal of second phase was to maintain the goals achieved in 1st phase and to increase the range and strength of knee and hip joint.

In this report we are discussing a case of 35 year old male with supracondylar femur fracture with difficulty in extending the leg. The main aim of physiotherapy management was to maintain the available range and to increase knee flexion and extension range. Distal femoral fractures should be treated using the same metrics and standards of care that are now used for hip fractures [7,8].

Exercises from phase one were continued with repetition increased to 15 .To improve the range, heel slides were initiated. In heel slides the patient is asked to move the lower limb by

Table 2. On the last day of rehabilitation, the ROM of the joint assessed

Joint	Active ROM (in degrees)	Passive ROM (in degrees)
Knee Joint	0-90	0-110

Continues passive movement is the method been used since long time but less evidence is seen regarding the effectiveness of CPM in increasing the range of motion. Following LISS plate attachment, the evidence base proved to be consistent in the restriction of weight-bearing during physiotherapy exercises. According to the research, starting weight-bearing too soon can lead to implant failure and mal-union. Non-weight bearing, toe-touch, and partial weight-bearing, on the other hand, have a significant difference in energy expenditure and technical competence [9,10].

5. CONCLUSIONS

Supracondylar femoral fracture is a challenging condition to deal with and is associated with many secondary complications. In the rehabilitation and care of patients with supracondylar femur fractures, a physiotherapist plays a crucial role.

CONSENT

Informed consent was taken in written after explaining the whole procedure to the patient.

ETHICAL APPROVAL

As per international standard or university standard written ethical approval has been collected and preserved by the author(s).

COMPETING INTERESTS

Authors have declared that no competing interests exist.

REFERENCES

1. Li J, Ding Y, Guo X, Guo W, Gao B, Wang J. Teaching application of hand-foot-combined-usage in Supracondylar Fracture of Femur. Asian Journal of Surgery. 2021;44(3):582–4.
2. Figgie MP, Goldberg VM, Figgie HE, Sobel M. The results of treatment of supracondylar fracture above total knee arthroplasty. The Journal of Arthroplasty. 1990;5(3):267–76.
3. Ehlinger M, Ducrot G, Adam P, Bonnomet F. Distal femur fractures. Surgical techniques and a review of the literature. Orthopaedics & Traumatology: Surgery & Research. 2013;99(3):353–60.
4. Steinberg EL, Elis J, Steinberg Y, Salai M, Ben-Tov T. A double-plating approach to distal femur fracture: A clinical study. Injury. 2017;48(10):2260–5.
5. Gangavalli AK, Nwachuku CO. Management of Distal Femur Fractures in Adults. Orthopedic Clinics of North America. 2016;47(1):85–96.
6. Smith TO, Hedges C, MacNair R, Schankat K. Early rehabilitation following less invasive surgical stabilisation plate fixation for distal femoral fractures. Physiotherapy. 2009;95(2):61–75.
7. Phansopkar P, Naqvi WM. Early physiotherapy rehabilitation approach enhances recovery in rare acute tibial osteomyelitis post-operative in a 9 year old child. 2020;5.
8. Siroya V, Fernandes L, Wadhokar OC. A Pioneering Physiotherapeutic Approach to the Treatment of a COVID Affected Patient – A Case Report. Journal of Pharmaceutical Research International. 2021;17–24.
9. Prat-Fabregat S, Camacho-Carrasco P. Treatment strategy for tibial plateau fractures: An update. Efort Open Rev. 2016;1(5):225–32.
10. Joshi M. Early Pulmonary Rehabilitation Approach Towards Complicated Case Of Acute Respiratory Failure: Enhancing Quality Of Life. JMPAS. 2021;10(3):2809–12.

© 2021 Kochar et al.; This is an Open Access article distributed under the terms of the Creative Commons Attribution License (<http://creativecommons.org/licenses/by/4.0>), which permits unrestricted use, distribution, and reproduction in any medium, provided the original work is properly cited.

Peer-review history:
The peer review history for this paper can be accessed here:
<https://www.sdiarticle5.com/review-history/76974>