

A Rare Case of Round Ligament Leiomyoma Masquerading as Inguinal Hernia

**Mishra Jagannath^{a†}, Khandelwal Richi^{a†*}, Padhy Ashok^{a‡},
Mohapatra Janmejay^{a‡} and Parija Jita^{a#}**

^a Department of Gynaecological Oncology, Acharya Harihar Post Graduate Institute of Cancer,
Cuttack, Odisha, India.

Authors' contributions

This work was carried out in collaboration among all authors. All authors read and approved the final manuscript.

Article Information

Editor(s):

(1) Dr. Lomas Kumar Tomar, National University of Ireland, Ireland.

Reviewers:

(1) Devang Bharti, ABVIMS & Dr. RML Hospital, India.

(2) José-María Sánchez-Merino, University Hospital A Coruña, Spain.

(3) Greco Dalila Patrizia, Italy.

Complete Peer review History, details of the editor(s), Reviewers and additional Reviewers are available here:
<https://www.sdiarticle5.com/review-history/81405>

Case Study

**Received 21 October 2021
Accepted 27 December 2021
Published 29 December 2021**

ABSTRACT

Smooth muscle tumors originating from round ligament are rare with leiomyoma being the most common type among them with unknown exact incidence. Its location at inguinal area/pubis area is confused with the clinical diagnosis of vulvar swelling, inguinal hernia, lymph node, or other nodal masses. Preoperative diagnosis is usually done by a computed tomography or an exploration of the affected area. Curative treatment is excision of the mass. Here, we report a case of a 47-year-old parous woman who presented with swelling over right inguinal region, on exploration, a myoma was found and was confirmed as leiomyoma on histopathology.

Keywords: Round ligament; leiomyoma; inguinal hernia.

[†]MCh Resident;

[‡]Assistant Professor;

[#]Professor and HOD;

*Corresponding author: E-mail: richikhandelwal1043@gmail.com;

1. INTRODUCTION

The round ligament of uterus attaches the uterus to the mons pubis and labia majora through the inguinal canal. It is composed of connective tissue, smooth muscle fibers, arteries, veins and nerves with a coating of mesothelial layer [1,2]. Tumor of the round ligament of uterus is rare, with leiomyoma being the most common followed by mesothelial cysts and endometriosis [1]. Leiomyoma usually originates from smooth muscle fibers in round ligament [3].

Abdominal, inguinal, and vulvar locations of round ligament leiomyoma have been described [4,5]. There are few case reports and case series in the literature but the exact incidence is not known [6]. leiomyomas are frequently encountered during reproductive years but there are also reports of menopausal occurrences . Mean age of the patients varies between 13 and 70 years and mean dimension of tumor from 0.5 to 15 cm [7]. Extra peritoneal round ligament leiomyomas are uncommon tumors. Hence, we report this rare case of leiomyoma of round ligament, presenting as a painless swelling over right inguinal region.

2. CASE REPORT

A 47-years-old female patient presented to the outpatient department of gynecological oncology,

AHPGIC, Cuttack with painless swelling over right inguinal region. Swelling had been gradually increasing in size for the past 6 months and was not reducible. The swelling measured 7 x 5 cm, was irreducible, and non-tender. On speculum and bimanual pelvic examination, cervix was found to be healthy, uterus was bulky, irregular in shape and contour with no adnexal masses. Preoperative transvaginal ultrasonography revealed multiple myomas with the largest being 5x4 cm and a well circumscribed 7 x 5 cm lesion over the right inguinal area and the ovaries seemed normal.

With the above mentioned findings, right inguinal region was explored surgically and a well-circumscribed firm mass of size approximately 7 cm x 5 cm x 4 cm was found. The mass was found to be originating from the inguinal insertion of round ligament [Fig. 1] and was removed completely. As there were multiple myomas [Fig. 2] in the uterus we proceeded with abdominal hysterectomy as patient had completed family. The excised specimen was sent to the pathology department for histopathological examination. The round ligament mass on microscopic examination revealed features of leiomyoma [Fig. 3]. The patient was discharged on day 3 post operative.

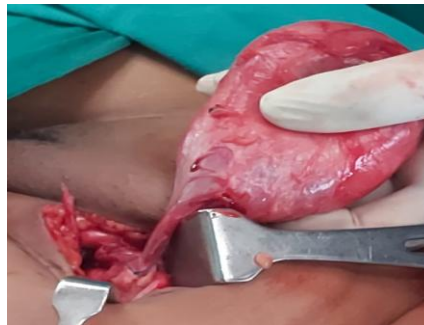


Fig. 1. Showing origin of leiomyoma from round ligament of uterus

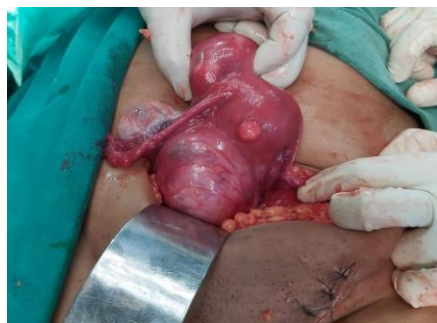

Fig. 2. Showing associated multiple leiomyoma of uterus

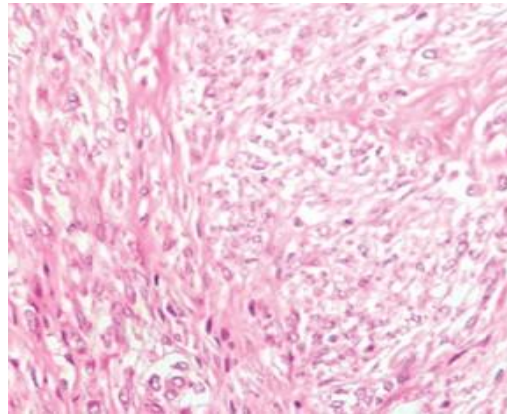


Fig. 3 Microscopic view showing spindle cells in fascicles (High power view) suggestive of leiomyoma

3. DISCUSSION

Tumors of the round ligament of uterus are quite rare. The most common ones are leiomyomas, endometriosis and mesothelial cysts [1]. 50- 70% of leiomyomas occur in the extra peritoneal part of the round ligament and are more common on the right side for unknown reasons [1]. Fifty percent of round ligament leiomyomas present with uterine fibroids as in our case [8,9]. They are commonly seen in young patients and estrogen and progesterone receptors are positive. However, there had been reports of cases which are diagnosed in postmenopausal females [7,10]. It can mimic as vulvar mass or inguinal hernia as in our case or inguinal lymphadenopathy. Preoperatively computed tomography scan and magnetic resonance imaging (MRI) [11,12] shows an encapsulated heterogeneous mass associated with calcifications which helps in making diagnosis; [13], but these are non-specific findings. Surgical exploration is the only definitive method to differentiate between leiomyoma, inguinal lymphadenopathy, and inguinal hernia. The final diagnosis is confirmed on histopathology. So it can be considered as one of the differential diagnosis of inguinal region mass in female patient.

4. CONCLUSION

Leiomyoma of the round ligament of uterus is a rare entity and can be mistaken for inguinal hernia. Pre-operative diagnosis can be suspected by CT scan. Treatment of choice is excision which provides symptomatic relief to the patient. Diagnosis is usually made intra operatively and confirmed by histopathological examination.

CONSENT AND ETHICAL APPROVAL

As per university standard guideline, participant consent and ethical approval have been collected and preserved by the authors.

COMPETING INTERESTS

Authors have declared that no competing interests exist.

REFERENCES

1. David MW, Stanley RM. Leiomyoma of extra peritoneal round ligament: CT demonstration. *Clin Imaging* 1999;23: 375–6.
2. Williams PL, Bannister LH, Berry MM, Collins P, Stain M, Dussek JE, et al. Eds. *Grey's Anatomy*. 38th Ed. New York: Churchill Livingstone. 1995;1874.
3. Mettingly RF, Woodruff JO. Surgical conditions of the vulva, in Te Linde's *Operative Gynecology*, J. B. Lippincott, Philadelphia, Pa, USA, 6th Edition. 1985;697–699.
4. Alexander L, Maria GHA, Christian K, Gerhard B, Johann L. Leiomyoma of the round ligament in a post-menopausal woman. *Maturitas*. 1999;31:133–5.
5. Ryan GL, Syrop CH, Van Voorhis BJ. Role, epidemiology, and natural history of benign uterine mass lesions. *Clin Obstet Gynecol*. 2005;48:312-24.
6. N Fasih, Shanbhogue AKP, Macdonald DB et al. Leiomyomas beyond the uterus: Unusual locations, rare manifestations. *Radiographics*. 2008;28(7): 1931–1948.

7. Noyan V, Yücel A, Atasoy P, Bayram M. Superficial genital leiomyoma: A case report. *Turkiye Klinikleri Journal of Gynecology and Obstetrics*. 2002;12(1): 104–106.
8. Bhosale PR, Patnana M, Viswanathan C, Szklaruk J. The inguinal canal: Anatomy and imaging features of common and uncommon masses. *Radiographics*. 2008;28(3):819–835.
9. Colak E, Ozlem N, Kesmer S, Yildirim K. A rare inguinal mass: Round ligament leiomyoma. *Int J Surg Case Rep*. 2013;4:577-8.
10. Christodoulou IM, Angelopoulos A, Siaperas P, Ioannidis A, Skarpas A, Tellos A, et al. Leiomyoma of the round ligament of the uterus mimicking inguinal hernia. *Case Rep Surg* 2018;2018: 6702494.
11. Michel P, Viola D. Abdomino-pelvic leiomyoma of the round ligament: Contribution of computed tomography and magnetic resonance imaging. *J Gynecol Obstet Biol Reprod (Paris)*. 2003;32: 571–4.
12. Birge O, Arslan D, Kinali E, Bulut B. Round ligament of uterus leiomyoma: An unusual cause of dyspareunia. *Case Rep Obstet Gynecol*. 2015;2015:197842.
13. Harish E, Sowmya NS, Indudhara PB. A rare case of round ligament leiomyoma: An inguinal mass. *J Clin Diagn Res*. 2014; 8:105–6.

© 2021 Jagannath et al.; This is an Open Access article distributed under the terms of the Creative Commons Attribution License (<http://creativecommons.org/licenses/by/4.0>), which permits unrestricted use, distribution, and reproduction in any medium, provided the original work is properly cited.

Peer-review history:

The peer review history for this paper can be accessed here:
<https://www.sdiarticle5.com/review-history/81405>