



## **Kikuchi Fujimoto Disease – A Diagnostic Challenge**

**Sushil Deshpande<sup>1</sup> and Dinesh Kulkarni<sup>2\*</sup>**

<sup>1</sup>Sanket Nursing Home, Auranganbad - 431005, Maharashtra, India.

<sup>2</sup>Saurabh Histopathology Centre, Aurangabad - 431005, Maharashtra, India.

### **Authors' contributions**

*This work was carried out in collaboration between both authors. Author SD carried out the surgery, searched literature and modified manuscript. Author DK processed the specimen, diagnosed the case, searched literature and prepared the manuscript. Both authors read and approved the final manuscript.*

### **Article Information**

#### Editor(s):

(1) Dr. José Francisco de Sales Chagas, Sao Leopoldo Mandic Medical School, Brazil.

#### Reviewers:

(1) Rajesh Kumar Bhola, IMS & SUM Hospital, India.

(2) Bhavana Singh, Kwame Nkrumah University of Science and Technology, Ghana.

Complete Peer review History: <https://www.sdiarticle4.com/review-history/69383>

**Case Report**

**Received 20 April 2021**

**Accepted 23 June 2021**

**Published 13 July 2021**

### **ABSTRACT**

Kikuchi-Fujimoto Disease is an extremely rare entity characterized by subacute necrotizing lymphadenitis and frequently associated with fever. It is known to have a worldwide distribution with higher prevalence among Japanese and other Asiatic young individuals. The clinical, histopathological and immunohistochemical features appear to point to a viral etiology, a hypothesis that still has not been proven and the cause remains uncertain. It is generally diagnosed on the basis of an excisional biopsy of affected lymphnodes. Early diagnosis with excisional lymph node biopsy is crucial as this disease can be mistaken for Systemic Lupus Erythematosus (SLE) or lymphoma and to avoid unnecessary investigations. The treatment is only symptomatic unless complicated, where steroid therapy is considered. Kikuchi's disease has an excellent prognosis with almost no risk. Because of the rarity and difficulty in diagnosis, we thought of publishing the case.

**Keywords:** Necrotising Lymphadenitis; adults; Asia.

\*Corresponding author: E-mail: [drdineshkulkarni@gmail.com](mailto:drdineshkulkarni@gmail.com);

## 1. INTRODUCTION

Kikuchi Fujimoto Disease (KFD) was first reported in Japan almost simultaneously by Kikuchi [1] and Fujimoto [2] in 1972. It is a benign and self-limiting disease that classically presents with lymphadenopathy and fever. The etiology is poorly understood. The searched literature did not show incidence rates. Although seen worldwide, it is known to be much more prevalent in Asian populations [3]. Indeed, a comprehensive literature review of KFD cases in 2003 described it as being "scarce in the western world" [4]. KFD is prevalent in younger population [3,4,5]. Histologically, lymphadenitis is characterized by paracortical lymph node expansion with patchy, well-circumscribed areas of necrosis showing abundant karyorrhectic nuclear debris and absence of neutrophils and eosinophils. The histological differential diagnosis of KFD includes reactive lesions as lymphadenitis associated with Tuberculosis, Histoplasmosis, Leprosy, Syphilis, Infectious mononucleosis, SLE or herpes simplex, non-Hodgkin's lymphoma, plasmacytoid T-cell leukemia, myeloid tumor and even metastatic carcinoma [5]. Treatment is symptomatic with analgesics-antipyretics, non-steroidal anti-inflammatory drugs and, rarely, corticosteroids. Spontaneous recovery occurs in 1 to 4 months. Patients with Kikuchi-Fujimoto disease need long term follow up to survey the possibility of the development of SLE.

## 2. CASE REPORT

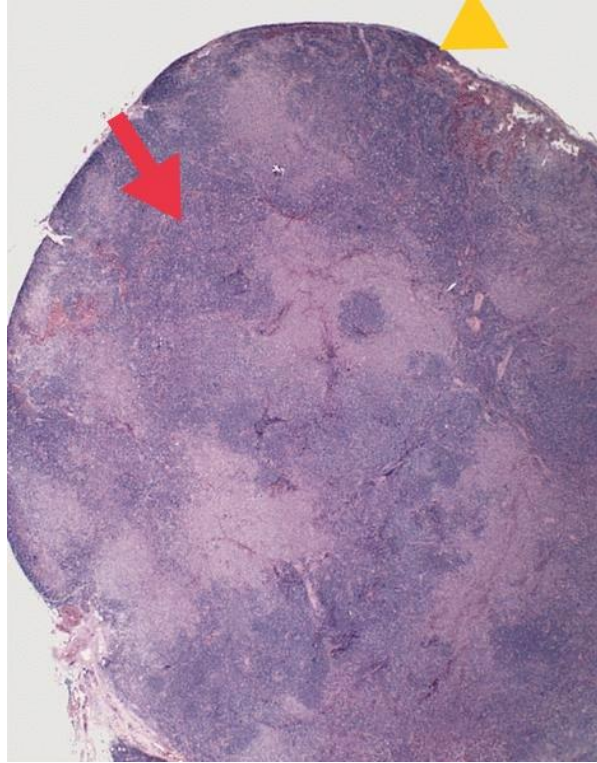
A 32-year male was referred for cervical lymphnode biopsy having multiple bilateral neck nodules associated with low grade fever, for last four months. The size of nodules was increasing slowly and didn't respond to a course of antibiotics prescribed by his physician. On examination the nodules were multiple, nonmatted, soft to firm, freely mobile, nontender with largest being of size 2x2 cm. He also had bilateral axillary lymphadenopathy. He didn't have history of allergy. His systemic examination i.e. Cardiovascular, Respiratory, Abdominopelvic and Nervous systems were within normal limits. A possible diagnosis of tuberculosis was considered and the patient was sent for investigations. Complete blood count showed lymphocytosis and elevated E.S.R. (20 mm at the end of one hour by Wintrobe's method). Rest all parameters were within normal limits. His X-ray chest was done and was reported by radiologist as (Rt) hilar lymphadenopathy likely of

infective origin, rest of the lung parenchyma and bony cage did not show any abnormality. The Tuberculin test had induration of 3 mm after 48 hours. With multiple lymphadenopathies, he was referred for USG Abdomen and Pelvis, which ruled out hepatosplenomegaly and abdominal lymphadenopathy. (Rt) neck cervical lymphnode biopsy was done, two intact nodes were removed and sent for histopathology examination. On gross examination, two whitish rounded 2x1 and 1.5x1 cm soft tissue masses were seen. Cut surface had capsule and uniform whitish areas. No caseation was seen. Histologically the sections showed fibrous capsule and beneath maintained lymphoid architecture (Fig. 1) with paracortical expansion by necrotic areas showing admixture of histiocytes, plasmacytoid dendritic cells, lymphocytes and karyorrhectic debris.(Fig. 2) No neutrophils or eosinophils were seen. There was no evidence of Reed Sternberg cells, granuloma or metastatic deposits. Ziehl Neelsen (ZN) stain was negative for acid fast bacilli. The diagnosis of Lymphadenitis of Kikuchi Fujimoto type was conveyed. On immunohistochemistry (IHC), CD 20 and CD 3 highlighted "B" and "T" lymphocytes, CD 68 histiocytes, CD 123 plasmacytoid dendritic cells and CD 30 highlighted scattered immunoblasts. Ki 67 was 95% in lymphoid follicles and 15% in interfollicular areas. Thus, IHC ruled out lymphoma and also confirmed our diagnosis.

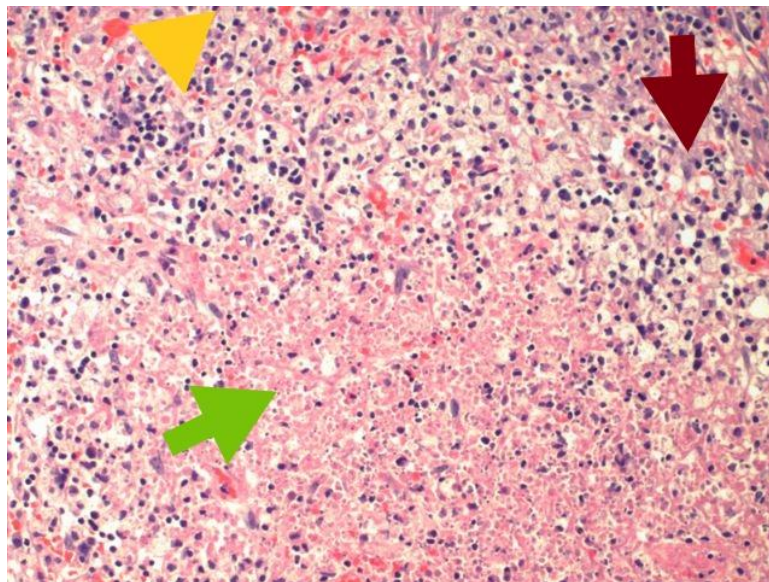
## 3. DISCUSSION

Kikuchi Fujimoto Disease was discovered in 1972 in Japan by two separate groups. Its exact incidence is unknown, but it is more prevalent in East Asia. Kikuchi's disease is seen more frequently in young adults, with a mean age between 20–30 years but it can occur in any age group. Even though a female predominance is reported in many previous cases, some studies done in Asia show a male to female ratio of 1:1. [4,5] The definitive diagnosis of KFD can be made only through lymph node biopsy and histological examination. Even with adequate tissue the lymph node appearances can be mistaken for malignant lymphoma; in one study, 30% of lymph node biopsies in KFD were initially misdiagnosed as lymphoma. The histopathological features of KFD have been classified into three stages: (1) proliferative stage, with expression of histiocytes, plasmacytoid monocytes, and lymphoid cells containing karyorrhectic nuclear fragments and eosinophilic apoptotic debris; (2) necrotizing stage, with a degree of coagulative necrosis; and (3) xanthomatous stage, with foamy histiocytes

predominating. A characteristic and useful diagnostic feature is the absence of granulocytes in the “necrotizing stage”, which is helpful in distinguishing KFD from SLE and drug induced lymphadenopathy. [4,5].



**Fig. 1. shows fibrous capsule (yellow arrow head) and beneath lymphnode architecture maintained and hyperplastic follicles (red arrow) and dilated sinuses. (H & E 5x X 10x)**



**Fig. 2. shows areas of necrosis (green arrow) surrounded by chronic inflammatory cells (yellow arrowhead) and histiocytes (red arrow) ( H & E 10x X 40x)**

#### 4. CONCLUSION

Kikuchi-Fujimoto disease poses significant diagnostic challenges to pathologists and clinicians as it can easily be mistaken for other benign lymphadenopathies or infectious lymphadenitis as well as lymphomas. Clinicians' and pathologists' awareness of this disorder can help to avoid misdiagnosis of lymphoma and prevent further expensive and invasive investigations, as well as potentially harmful treatments and psychological stress to the patient. Excisional lymph node biopsy provides the optimal specimen for diagnosis of KFD.

#### CONSENT

As per international standard or university standard, patient's consent has been collected and preserved by the authors.

#### ETHICAL APPROVAL

It is not applicable.

#### COMPETING INTERESTS

Authors have declared that no competing interests exist.

#### REFERENCES

1. Kikuchi M. Lymphadenitis showing focal reticulum cell hyperplasia with nuclear debris and phagocytes: A clinicopathological study. *Acta Hematol Jpn* 1972;35:379-380.
2. Fujimoto Y, Kozima Y, Yamaguchi K: Cervical subacute necrotizing lymphadenitis: A new clinicopathologic entity. *Naika*. 1972;20:920-927.
3. Xavier Bosch, Antonio Guilabert. Kikuchi-Fujimoto disease. *Orphanet Journal of Rare Diseases*. 2006;1:18
4. Matthew R Wilson, Gordon Milne, Evangelos Vryonis. Kikuchi-Fujimoto Disease: A Rare Cause of Fever in the Returning Traveller. *Case Reports in Medicine*. 2014. Article ID 868190,
5. Anamarija M Perry, Sarah M. Choi Kikuchi-Fujimoto Disease: A Review *Arch Pathol Lab Med*— 2018;142.

© 2021 Deshpande and Kulkarni; This is an Open Access article distributed under the terms of the Creative Commons Attribution License (<http://creativecommons.org/licenses/by/4.0>), which permits unrestricted use, distribution, and reproduction in any medium, provided the original work is properly cited.

*Peer-review history:*  
*The peer review history for this paper can be accessed here:*  
<https://www.sdiarticle4.com/review-history/69383>