

# Efficacy and Safety of Laser Photocoagulation in Persistent Idiopathic Central Serous Chorioretinopathy: A Prospective Interventional Study

RAMA BALASAHEB KALEKAR<sup>1</sup>, SHAILENDRA SAVALERAM DESHMUKH<sup>2</sup>

## ABSTRACT

**Introduction:** Central Serous Chorioretinopathy (CSCR) encompasses the macular area, secondary to the accumulation of subretinal fluid and increased permeability from the choriocapillaris resulting in focal or diffuse dysfunction of the retinal pigment epithelium. Diagnosis of CSCR is done by several procedures like clinical examination, Amsler grid testing, fluorescein angiography, ocular coherence tomography. There are several treatment options including photodynamic therapy, laser photocoagulation, etc., for CSCR.

**Aim:** To study the efficacy and safety of laser photocoagulation in persistent idiopathic CSCR.

**Materials and Methods:** The present prospective interventional study was conducted in the Department of Ophthalmology, BJ Government Medical College and Sassoon General Hospital, Pune, Maharashtra, India, from August 2019 to January 2021. A total of 30 patients (30 eyes) with idiopathic CSCR, persistent for duration of three months or more with worsening of visual symptoms, active leakage on Fundus Fluorescein Angiography (FFA) were subjected to 532 nm subthreshold green laser photocoagulation treatment after routine investigations. Statistical analysis was done on International Business Machines (IBM) Statistical Package for the Social Sciences (SPSS) software version 20.0.

**Results:** In the present study, there was male preponderance (86.7%) for the CSCR cases. The mean±Standard Deviation (SD)

age of in the study was 37.7±0.07 years. All the eyes studied had unilateral involvement with 53.35% right eye involvement and 46.7% left eye involvement. The duration of current episode of CSCR in months showed a mean±SD of 5.86±1.40. The distribution of visual acuity in affected eye (before laser treatment) depicts the mean pre-laser Best Corrected Visual Acuity (BCVA) of 30 patients at baseline was (0.68±0.20) in LogMAR. About 67% patients experienced central scotoma and 33% patients had metamorphopsia on Amsler chart. Distribution of active leakage site on FFA showed that 43% cases had active leakage in superonasal quadrant, 30% had active leakage in superotemporal, 17% had active leak in inferonasal quadrant and 10% had active leak in inferotemporal quadrant. CSCR associated with or without Retinal Pigment Epithelium (RPE) atrophy showed that 63.3% patients had RPE atrophy suggesting long-standing course of disease with NSD and subretinal fluid collection affecting RPE. Pre-laser mean CMT on OCT of affected eye was 445.83±54.79 μm which was reduced to mean CMT of 303.57±48.49 μm at four weeks follow up, which further reduced to mean CMT of 224.9±20 μm at end of 12 weeks was statistically significant with p-value<0.001. The statistical analysis for the macular thickness at four weeks and 12 weeks showed significant probability with paired t-test with p-value<0.001.

**Conclusion:** It can be concluded from the present study that early treatment with laser photocoagulation is efficient in the restoration of vision within a period of 12 weeks.

**Keywords:** Central serous chorioretinopathy, Fundus fluorescein angiography, Laser photocoagulation, Macular thickness, Neurosensory retinal detachment

## INTRODUCTION

Central Serous Chorioretinopathy (CSCR) is a retinal disease characterised by serous detachment of the Neurosensory Retina (NSR) occurring due to one or more focal lesions of the Retinal Pigment Epithelium (RPE). CSCR characterised by serous detachment of neurosensory retina secondary to accumulation of subretinal fluid and increased permeability from choriocapillaris resulting in focal or diffuse dysfunction of retinal pigment epithelium leading to detachment of the neurosensory retina [1]. CSCR is generally a middle age disease with male predominance (male to female ratio is 6:1). Disease mostly seen in Caucasians, Hispanics, Asians. Type A personality, stress, increased cortisol level, systemic diseases like hypertension, DM, cardiovascular disease, obstructive sleep apnea, alcohol addiction, smoking are risk factors for CSCR [2,3,4]. The principal symptoms of CSCR include blurring of vision (frequently in one eye) and perception by the patient as a dark spot in the centre of the visual field with associated micropsia, metamorphopsia, scotomas with complete reversibility to normal

vision occurring within few months [5]. The acute form of the disease state is usually self-limited, with spontaneous resorption of the subretinal fluid in most patients within 3-4 months leaving mostly color discrimination defects in a few patients and the chronic occurrence of the fluid causes atrophy of the photoreceptors and retinal pigment epithelium, possibly leading to a severe central visual loss [1]. The chronic form, also called as diffuse retinal epitheliopathy is characterised by extensive tracks of RPE atrophy exhibiting reduced Fundus Autofluorescence (FAF) with or without Serous Retinal Detachment (SRD) [6,7]. Diagnosis of CSCR done by clinical examination, dilated fundus examination, amsler grid testing, FFA, ICGA, OCT, microperimetry, multifocal ERG. Amsler grid testing illustrates the metamorphopsia in eyes with near-normal visual acuity and dilated fundus examination with biomicroscopy and indirect ophthalmoscopy facilitates to establish the characteristic finding of CSCR [8]. Fluorescein angiography is often used to CSCR and rule out other conditions. Even though there is no universal agreement with respect to the most suitable treatment algorithm, numerous

treatment options are available, including observation, diuretics, photodynamic therapy, laser photocoagulation and anti Vascular Endothelial Growth Factor (VEGF) therapy [3]. Hence, the present study was conducted with the primary aim to study the efficacy and safety of laser photocoagulation in persistent idiopathic CSCR. The study also aimed to assess the efficacy of laser photocoagulation in terms of improvement in best corrected visual acuity and reduction in macular thickness with resolution of subretinal fluid in persistent idiopathic CSCR and study the complications associated with it.

## MATERIALS AND METHODS

The present prospective interventional study was conducted in the Department of Ophthalmology, BJ Government Medical College and Sassoon General Hospital, Pune, Maharashtra, India, from August 2019 to January 2021. Approval of Institutional Ethics Committee (IEC number=1119231-231) was obtained and patients were selected from the Outpatient Department of Ophthalmology. The patients diagnosed with persistent non resolving central serous chorioretinopathy with duration of three months or more were selected and informed about the nature of the study. Written informed consent was obtained from all the patients who were willing to participate in the study and then a total of 30 eyes of 30 patients were included. Patients were admitted in the ward and underwent laser photocoagulation at active leakage site and follow-up was done after four weeks and 12 weeks.

**Inclusion criteria:** All new and review cases of idiopathic CSCR persistent for duration of three months or more within 20-50 years of age group were included in the study.

**Exclusion criteria:** Self-resolving CSCR cases, patients on steroid treatment for any systemic cause, patients with other pre-existing retinal pathology or ocular infective condition, prior laser therapy or anti-VEGF injection taken in study eyes and patients allergic to fluorescein dyes were excluded from the study.

### Study Procedure

Evaluation of patients includes detailed preliminary history including diminution of vision and other ophthalmic complaints, duration of symptoms, any relieving or exacerbating factors, past ocular history, history of similar episodes in past, history of any ocular treatment, significant systemic history and drug history or any family history, history of any addiction and mental stress. Detailed ocular examination was done with:

- ♦ Visual acuity assessment using Snellen's and LogMAR charts.
- ♦ Amsler chart evaluation.
- ♦ Colour vision.
- ♦ Intraocular pressure measurement by non contact tonometry/applanation tonometry.
- ♦ Slit lamp biomicroscopy.
- ♦ Detailed fundus examination using direct and indirect ophthalmoscopy and slit lamp biomicroscopy using 90D lens.
- ♦ Optical Coherence Tomography (OCT).
- ♦ Fundus Fluorescein Angiography (FFA).

### Ocular examination:

- ♦ **Visual acuity:** Both uncorrected and best corrected visual acuity was recorded with Snellen's chart and log-MAR visual acuity charts. Near vision testing was done with Jaeger chart, colour vision using Ishihara pseudoisochromatic plates.
- ♦ **Intraocular pressure:** Intraocular pressure was measured using Goldman applanation tonometer.
- ♦ Amsler grid examination.
- ♦ **Slit lamp biomicroscopy:** Slit lamp examination was done to assess the adnexa, lid margins, eyelashes, puncta, tear film, conjunctiva, cornea, anterior chamber, iris, pupil and lens. Slit lamp biomicroscopy (90D).

- ♦ **Fundus examination:** Patient's eyes were dilated with 1% tropicamide and 5% phenylephrine combination drops. Fundus examination was done with 90D lens on slit lamp and with the help of direct ophthalmoscopy and indirect ophthalmoscopy using 20D lens.
- ♦ **Fundus photography:** was taken to record posterior segment findings in picture form using Zeiss visucam 524 fundus cameras.
- ♦ **Optical Coherence Tomography (OCT):** It is to determine central macular thickness; Neurosensory detachment with or without PED and subretinal fluid height.
- ♦ **Fundus Fundus Fluorescein Angiography (FFA):** It was done to look for active angiographic leakage, site of leakage and pattern of leakage like inkblot or smoke stack leakage or granular hyperfluorescence with atrophic RPE track, paucifocal or multifocal leakage.

Thorough laboratory work-up was carried with Complete Blood Count (CBC) and haemoglobin, blood sugar level profile, lipid profile, renal function tests like blood urea, serum creatinine, blood pressure and electrocardiogram. Patients diagnosed with central serous chorioretinopathy persistent for more than three months with worsening of visual symptoms over the time and active leakage on fundus fluorescein angiography underwent laser photocoagulation at active leakage site. Thereafter, patients were followed-up at 4 weeks and 12 weeks. Study was carried out according to the protocol and any new amendments to protocol informed to concerned authority. Patient information obtained was kept confidential and only competent authorities i.e. Independent Ethics Committee, Institutional Review Board were allowed to access the records. Medical records were treated confidentially and only that data, which does not identify the patient, were shared with the above and may be published.

**Technique:** Thirty eyes of 30 patients with idiopathic CSCR persistent for duration of three months or more with worsening of visual symptoms, active leakage on fundus fluorescein angiography were subjected to 532 nm subthreshold green laser photocoagulation treatment after baseline investigations and after finding active leakage site on fundus fluorescein angiography. Single retinal specialist performed FFA and laser photocoagulation. The laser system used was IRIS IQ medical 532 nm green laser delivery system, which allows setting for subthreshold delivery. The laser treatment was done using the same device using Area Centralis VolkTM lens. The energy was set to 100 mW initially and titrated by 10 mW until minimal white burn with a spot size of 100 µm and pulse duration of 0.1 second. Multiple confluent, non overlapping spots applied over areas of focal and diffuse RPE leak. Besides the leak point, authors treated the area approximately five to six spots around the leak points in areas of fluid collection sparing fovea. Patients were followed-up after 4 weeks and 12 weeks to look for any change in visual acuity, any worsening or improvement of symptoms, change in Central Macular Thickness (CMT) on OCT. At each follow-up visits, patients were subjected to visual acuity testing, Amsler chart testing, slit lamp biomicroscopic examination followed by detailed fundus examination and OCT. Primary outcome measure was change in central macular thickness at end of 12 week of follow-up on OCT, change in BCVA at end of 12 week of follow-up and secondary outcome measure was any laser associated complications seen at the end of 12 weeks.

## STATISTICAL ANALYSIS

Primary data was collected in paper based proforma and the data was then entered in Microsoft Excel spreadsheets 2016. Statistical analysis was done on International Business Machines (IBM) Statistical Package for the Social Sciences (SPSS) software version 20.0. The comparative bar graphs and column graphs with mean were plotted. Distribution was represented by pie charts or

bar graphs. Column proportions was represented in percentage on bar or column charts, Continuous variables for same group in preoperative and postoperative observations were compared using paired t-test. The p-value <0.05 was considered statistically significant and p-value <0.01 was considered highly significant.

## RESULTS

The result shows, out of 30 cases, there were 26 (86.7%) males and 4 (13.3%) females with male preponderance for the CSCR cases. Age distribution of cases shows the mean age of 30 cases included in the present study was  $37.7 \pm 0.07$  years, with highest 46 years and lowest 31 years. Majority of the cases, i.e., 12 (40%) were from 31-35 years age group followed by 11 (36.7%) cases in 36-40 years age group, 6 (20%) cases in 41-45 years of age group and 1 (3.3%) case in 46-50 years age group. So, the most common age group involved in the present study was between 31-35 years of age. All the eyes studied had unilateral involvement. It was observed that 53.35% right eye involvement and 46.7% left eye involvement was present in the present study. [Table/Fig-1a,b] shows that 50% of patients in the present study had history of CSCR for 13-18 months. Overall duration of history of CSCR shows a mean of 16.93, median of 18.00 and SD of 4.37. [Table/Fig-2a,b] shows the mean duration of active current episode of CSCR of six months and maximum duration of active episode of CSCR of nine months in study group. The duration of current episode of CSCR in months shows a mean of 5.86, median of 6, SD of 1.40. [Table/Fig-3] shows the distribution of visual acuity in affected eye (before laser treatment) and depicts the mean prelaser BCVA of 30 patients at baseline was  $(0.68 \pm 0.20)$  in LogMAR.

Duration of history of CSR in months	
Mean	16.93
Median	18.00
Standard deviation	4.37
Minimum	10.00
Maximum	24.00

[Table/Fig-1a]: Showing overall duration of history of CSCR.

Duration	Frequency (n)	Percentage (%)
≤12 Months	7	23.3
13-18 months	15	50.0
19-24 months	8	26.7

[Table/Fig-1b]: Showing overall duration of history of CSCR.

Duration in months	Frequency (n)	Percentage (%)
4	5	16.66
5	8	26.66
6	9	30
7	4	13.33
8	2	6.66
9	2	6.66

[Table/Fig-2a]: Showing duration of current episode of CSCR in months.

Duration of current episode of CSCR in months	
Mean	5.86
Median	6
Standard deviation	1.40
Minimum	4
Maximum	9

[Table/Fig-2b]: Showing duration of current episode of CSCR in months.

Mean pretreatment best corrected Visual Acuity (VA) of affected eye was  $(0.68 \pm 0.20)$  in LogMAR. Patients were followed-up at 4 and 12 weeks after laser.

BCVA LogMAR	Frequency (n)	Percentage (%)
0.00	1	3.3
0.48	4	13.3
0.60	10	33.3
0.78	12	40.0
1.00	3	10.0
Total	30	100.0

[Table/Fig-3]: Distribution of visual acuity in affected eye (before laser treatment).

Mean postlaser best corrected visual acuity at 4 weeks was LogMAR  $(0.40 \pm 0.12)$  and mean postlaser BCVA at 12 weeks was improved to LogMAR  $(0.16 \pm 0.12)$  Improvement in visual acuity at end of 4 and 12 weeks was statistically significant with p-value <0.001 and out of 30 patients only one patient develop paracentral scotoma at the end of 12 week after laser.

In [Table/Fig-4], 67% patients experienced central scotoma and 10 (33%) patients had metamorphopsia on Amsler chart. Distribution of active leakage site on FFA showed that 13 (43%) patients had active leakage in superonasal quadrant, 9 (30%) had active leakage in superotemporal, 5 (17%) had active leak in inferonasal quadrant and 3 (10%) had active leak in inferotemporal quadrant. Majority of patients had active leakage in superonasal quadrant (43%) [Table/Fig-5]. CSCR associated with or without RPE atrophy was seen in [Table/Fig-6] and showed that 19 (63.3%) patients had RPE atrophy suggesting long-standing course of disease with NSD and subretinal fluid collection affecting RPE. In [Table/Fig-7] 16 patients (53.3%) in study group had associated Pigment Epithelial Detachment (PED) indicating common association of CSCR with PED. [Table/Fig-8] shows the distribution of change in central macular thickness before and after laser photocoagulation in CSCR. Prelaser mean CMT on OCT of affected eye was  $445.83 \pm 54.79$   $\mu$ m which was reduced to mean CMT of  $303.57 \pm 48.49$   $\mu$ m at four week follow up, which further reduced to mean CMT of  $224.9 \pm 20$   $\mu$ m at end of 12 weeks was statistically significant with p-value <0.001. The statistical analysis for the macular thickness at four weeks and 12 week s showed significant probability with paired t-test with p-value <0.001. [Table/Fig-9] depicts the distribution of visual acuity before and after

Amsler grid	Frequency (n)	Percentage (%)
Central scotoma	20	66.7
Metamorphopsia	10	33.3
Total	30	100.0

[Table/Fig-4]: Showing distribution of Amsler grid findings.

Site of leak	Frequency (n)	Percentage (%)
Superonasal quadrant	13	43.3
Superotemporal quadrant	9	30.0
Inferonasal quadrant	5	16.6
Inferotemporal quadrant	3	10.0
Total	30	100.0

[Table/Fig-5]: Distribution of active leakage site on FFA.

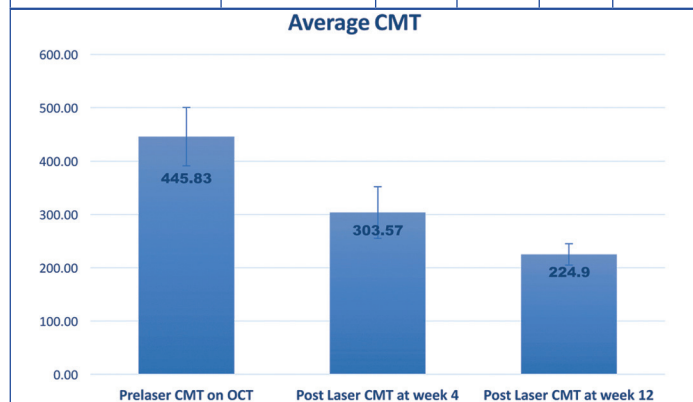
RPE atrophic track	Frequency (n)	Percentage (%)
Yes	19	63.3
No	11	36.7
Total	30	100.0

[Table/Fig-6]: CSCR associated with or without RPE atrophy.

Associated with PED	Frequency (n)	Percentage (%)
Yes	16	53.3
No	14	46.7
Total	30	100.0

[Table/Fig-7]: CSCR association with Pigment Epithelial Detachment (PED).

Paired samples statistics		Mean	N	SD	p-value
Prelaser to follow-up at 4 week change in CMT (µm)	Prelaser CMT on OCT	445.83	30	54.79	<b>&lt;0.001</b>
	Postlaser CMT at week 4	303.57	30	48.49	
Change in CMT (µm) on OCT Follow-up at 4 weeks to follow-up at 12 week	Postlaser CMT at week 4	303.6	30	48.49	<b>&lt;0.001</b>
	Postlaser CMT at week 12	224.9	30	20.02	



**[Table/Fig-8]:** Distribution of change in central macular thickness before and after laser photocoagulation in CSR. p-value in bold font indicates statistically significant values.

Paired sample statistics	Mean BCVA of affected eye in LogMAR	Standard deviation
Prelaser BCVA in LogMAR	0.68	0.20
Postlaser VA at 4 weeks	0.40	0.12
Postlaser VA at 12 weeks	0.16	0.12124

Paired samples statistics		Mean	N	SD	p-value
Prelaser to follow-up at 4 week change in BCVA	BCVA LogMAR	0.68	30.00	0.20	<b>&lt;0.001</b>
	Postlaser VA at 4 weeks	0.40	30.00	0.12	
Follow-up at 4 weeks to follow-up at 12 weeks change in BCVA	Postlaser VA at 4 weeks	0.4037	30	0.12	<b>&lt;0.001</b>
	Postlaser VA At 12 weeks	0.1610	30	0.12	

**[Table/Fig-9]:** Distribution of visual acuity before and after laser photocoagulation in CSR.

laser photocoagulation' mean pretreatment best corrected Visual Acuity (VA) of affected eye was (0.68±0.20) in LogMAR. Patients were followed-up at 4 and 12 weeks after laser. Mean postlaser best corrected visual acuity at 4 weeks was LogMAR (0.40±0.12) and mean postlaser BCVA at 12 weeks was improved to LogMAR (0.16± 0.12) Improvement in visual acuity at end of 4 and 12 weeks was statistically significant with p-value <0.001. [Table/Fig-10] shows the complications associated with 532 nm subthreshold green laser photocoagulation in CSR.

Complications	Frequency (n)	Percentage (%)
No complications	29	96.7
Paracentral scotoma	1	3.3
Total	30	100.0

**[Table/Fig-10]:** Complications associated with 532 nm subthreshold green laser photocoagulation in CSR.

## DISCUSSION

Acute Central serous chorioretinopathy is self-resolving disease in which neurosensory detachment and subretinal fluid resolves within 3-4 months so observation is first modality of treatment usually, however, chronic or recurrent cases results in permanent disorganisation in retinal elements with alterations including retinal thickening, cystoid changes to loss of photoreceptors [7]. It has

been reported that 20-50% of patients have recurrences in one year and chronic CSCR causes permanent visual loss [9-11]. The most common age group involved in the present study was between 31-40 years of age with mean age of 37.7 years which was analogous to previous studies done by Gass JD, Khatri A et al., OH J et al., and Altinel MG et al., [12-15]. Male predominance was evident from the results of the present study which was similar to the findings by Gass JD, OH J et al., and Altinel MG et al., [12,14,15]. In the present study, patients having CSCR persistent for three months or more with mean duration of current episode of 5.86±1.40 months, having visual disturbances, active leakage on FFA and mean overall duration of 16.93 months was reported. On FFA, granular hyperfluorescence in all the patients were observed with 63.3% patients having RPE atrophy due to persistent course of disease and 53% had associated pigment epithelial detachment. The mean pretreatment best corrected Visual Acuity (VA) of affected eye was (0.68±0.20) in LogMAR. Patients were followed-up at 4 and 12 weeks after laser mean postlaser best corrected visual acuity at 4 weeks was LogMAR (0.40±0.12) and mean postlaser BCVA at 12 weeks was improved to LogMAR (0.16±0.12) Improvement in visual acuity at end of 4 and 12 weeks was statistically significant with p-value <0.001. These findings were found to be in concordance with Khatri A et al., who found that the mean BCVA at pretreatment was 0.96 LogMAR (95% CI: 0.86-1.06, p-value<0.05) improving to mean BCVA of 0.18 (95% CI: 0.12-0.23, p-value<0.05) at five months follow-up [13]. Arsan A et follow-up [13]. reported median BCVA before treatment was 0.40 LogMAR and mean BCVA: 0.44±0.20 Snellen [16]. Median BCVA at three months after treatment was 1.0 (0.0 LogMAR) and the median BCVA at final follow-up was 1.00 (0.0 LogMAR). The BCVA was improved statistically significant at three months (p-value<0.001) and at the final follow-up (p-value<0.001), which was similar to the findings of the present study. In the present study, the statistical analysis for the macular thickness at 4 weeks and 12 weeks showed significant probability with paired t-test with t-test<0.001. Similarly, Yadav NK et al., have reported the use of yellow (577 nm) subthreshold laser for the treatment of chronic CSCR and had seen an average reduction in fluid height by 182 µm with (p-value<0.001) at mean follow-up of eight weeks [17]. Khatri A et al., reported mean decrease of CMT by 292 µm (95% CI: 194-389, p-value<0.05) which was statistically significant [13]. The present study results were coherent to the studies conducted by Lanzetta P et al., Yadav NK et al., Arsan A et al., [16,17,18]. In the present study, subthreshold green (532 nm) laser for treatment of persistent CSCR was used. Only one patient had developed paracentral scotoma at end of 12 weeks follow-up and no other complications were seen in the study group, indicating subthreshold green (532 nm) laser is relatively safer and effective modality in rapid restoration of vision and reduction of central macular thickness within 12 weeks. Similarly, Khatri A et al., used subthreshold green argon laser 532 nm reported no evidence of complications [13]. Yadav NK et al., used subthreshold micropulse diode laser (577 nm) reported no evidence of retinal pigment epithelium or retinal damage on Spectral-domain Optical Coherence Tomography (SDOCT), FFA, Fundus Autofluorescence (FAF) [17]. Viswanathan S and Velmurugan T concluded from their study that early treatment with laser photocoagulation produces early reduction in macular thickness in a better way than late or no treatment in patients with perifoveal leakage [19]. Wood EH et al., summarised recently available data in 398 patients of 16 studies on subthreshold retinal laser therapy on CSCR using various laser modalities from 532 nm continuous wave, 577 nm continuous wave and micropulse to 810 nm micropulse lasers and found that non damaging retinal laser efficiently reduces central macular thickness and improves visual acuity [20]. Similar findings were reported by Lanzetta P et al., Gupta B et al., Yadav NK et al., who showed analogous results without any major complications attributed to laser treatment, such as visible laser burns, choroidal neurovascular membranes, or retinal scars

with improvement in visual acuity and reduction in central macular thickness or subretinal fluid height following laser [17,18,21].

### Limitation(s)

Small sample size is one of the limitation, also larger follow-up period is needed to record any major complications like retinal scars or choroidal neurovascular membranes and recurrence. The green subthreshold 532 nm laser is used for the treatment of chronic CSCR with above results. There were not many studies done with the use of a green subthreshold laser for CSCR, hence, the present study results was compared with studies conducted using other spectrum of wavelength laser also.

### CONCLUSION(S)

There are numerous treatment options that are present for the treatment of patients with CSCR thus, providing an improved visual outcome. Although there are numerous studies on this subject, such research work is however limited by their retrospective non-randomised characteristic with small sample size and limited follow-up period. Thus, novel randomised controlled trials have facilitated to outline the treatment options for CSCR. Thus, it is imperative to distinguish that the consequences of treatment may be influenced by specific exogenous risk factors and treatment schedules require to be polished depending upon these. Thus, from the present study, it can be concluded that early treatment with laser photocoagulation is efficacious in the restoration of vision within a period of 12 weeks. However, further studies are recommended with long-term follow-up to determine the recurrence of CSCR and to record specific postlaser complications.

### REFERENCES

- [1] Wang M, Munch IC, Hasler PW, Prünke C, Larsen M. Central serous chorioretinopathy. *Acta Ophthalmol.* 2008 Mar;86(2):126-45.
- [2] Giannopoulos K, Gazouli M, Chatzistefanou K, Bakouli A, Moschos MM. The Genetic Background of Central Serous Chorioretinopathy: A Review on Central Serous Chorioretinopathy Genes. *J Genomics.* 2021 Jan 1;9:10-19.
- [3] Yoneyama S, Fukui A, Sakurada Y, Terao N, Shijo T, Kusada N, Sugiyama A, Matsubara M, Fukuda Y, Kikushima W, Parikh R, Mabuchi F, Sotozono C, Kashiwagi K. Distinct characteristics of central serous chorioretinopathy according to gender. *Scientific Reports.* 2022;12:14777-8.
- [4] Liew G, Quin G, Gillies M, Fraser-Bell S. Central serous chorioretinopathy: a review of epidemiology and pathophysiology. *Clin Exp Ophthalmol.* 2013 Mar;41(2):201-14.
- [5] Sahoo NK, Singh SR, Kamari P, Jonnadula GB, Das AV, Chhablani J. Prevalence and Profile of Central Serous Chorioretinopathy in an Indian Cohort. *Nepal J Ophthalmol.* 2019 Jan;11(21):5-10.
- [6] Imamura Y, Fujiwara T, Spaide RF. Fundus autofluorescence and visual acuity in central serous chorioretinopathy. *Ophthalmology.* 2011 Apr;118(4):700-5.
- [7] Teke MY, Elgin U, Nalcacioglu-Yuksekkaya P, Sen E, Ozdal P, Ozturk F. Comparison of autofluorescence and optical coherence tomography findings in acute and chronic central serous chorioretinopathy. *Int J Ophthalmol.* 2014 Apr 18;7(2):350-4.
- [8] Quin G, Liew G, Ho IV, Gillies M, Fraser-Bell S. Diagnosis and interventions for central serous chorioretinopathy: review and update. *Clin Exp Ophthalmol.* 2013 Mar;41(2):187-200. Doi: 10.1111/j.1442-9071.2012.02847.x. Epub 2012 Oct 17. PMID: 22788713.
- [9] Gilbert CM, Owens SL, Smith PD, Fine SL. Long-term follow-up of central serous chorioretinopathy. *Br J Ophthalmol.* 1984 Nov;68(11):815-20. doi: 10.1136/bjo.68.11.815. PMID: 6541945; PMCID: PMC1040477.
- [10] Loo RH, Scott IU, Flynn HW Jr, Gass JD, Murray TG, Lewis ML, Rosenfeld PJ, Smiddy WE. Factors associated with reduced visual acuity during long-term follow-up of patients with idiopathic central serous chorioretinopathy. *Retina.* 2002 Feb;22(1):19-24. doi: 10.1097/00006982-200202000-00004. PMID: 11884873.
- [11] Bujarborua D. Long-term follow-up of idiopathic central serous chorioretinopathy without laser. *Acta Ophthalmol Scand.* 2001 Aug;79(4):417-21. doi: 10.1034/j.1600-0420.2001.079004417.x. PMID: 11453866.
- [12] Gass JD. Bullous retinal detachment. An unusual manifestation of idiopathic central serous chorioidopathy. *Am J Ophthalmol.* 1973 May;75(5):810-21. doi: 10.1016/0002-9394(73)90887-8. PMID: 4196284.
- [13] Khatri A, Pradhan E, Singh S, Rijal R, Khatri BK, Lamichhane G, Kharel M. Going green-treatment outcome and safety profile of chronic central serous chorioretinopathy treated with subthreshold green laser. *Clin Ophthalmol.* 2018 Oct 5;12:1963-1971. Doi: 10.2147/OPHTH.S180663. PMID: 30323554; PMCID: PMC6178335.
- [14] Oh J, Yoon CK, Kim BH, Yu HG. Evaluation of the safety and efficacy of selective retina therapy laser treatment in patients with Central Serous Chorioretinopathy. *Korean J Ophthalmol.* 2021;35(1):51-63.
- [15] Altinel MG, Kanra AY, Totuk OMG, Ardagil A, Turkmen OF. Comparison of the efficacy and safety between subthreshold micropulse laser, standard-fluence and low-fluence photodynamic therapy for chronic central serous chorioretinopathy. *Journal Français d'Ophtalmologie.* 2021;44(4):499-508.
- [16] Arsan A, Kanar HS, Sonmez A. Visual outcomes and anatomic changes after sub-threshold micropulse yellow laser (577-nm) treatment for chronic central serous chorioretinopathy: long-term follow-up. *Eye (Lond).* 2018 Apr;32(4):726-733.
- [17] Yadav NK, Jayadev C, Mohan A, Vijayan P, Battu R, Dabir S, Shetty B, Shetty R; Medscape. Subthreshold micropulse yellow laser (577 nm) in chronic central serous chorioretinopathy: Safety profile and treatment outcome. *Eye (Lond).* 2015 Feb;29(2):258-64; quiz 265.
- [18] Lanzetta P, Furlan F, Morgante L, Veritti D, Bandello F. Nonvisible subthreshold micropulse diode laser (810 nm) treatment of central serous chorioretinopathy. A pilot study. *Eur J Ophthalmol.* 2008 Nov-Dec;18(6):934-40.
- [19] Viswanathan S, Velmurugan T. Clinical study in Central Serous Chorioretinopathy. *Evid Based Med health.* 2020;7(2):79-82.
- [20] Wood EH, Karth PA, Sanislo SR, Moshfeghi DM, Palanker DV. Non-damaging retinal laser therapy for treatment of central serous chorioretinopathy: What is the Evidence? *Retina.* 2017 Jun;37(6):1021-1033.
- [21] Gupta B, Elagouz M, McHugh D, Chong V, Sivaprasad S. Micropulse diode laser photocoagulation for central serous Chorioretinopathy. *Clin Exp Ophthalmol.* 2009 Nov;37(8):801-5.

#### PARTICULARS OF CONTRIBUTORS:

1. Resident, Department of Ophthalmology, BJGMC and SGH, Pune, Maharashtra, India.
2. Associate Professor, Department of Ophthalmology, BJGMC and SGH, Pune, Maharashtra, India.

#### NAME, ADDRESS, E-MAIL ID OF THE CORRESPONDING AUTHOR:

Rama Balasaheb Kalekar,  
Resident Quarters, BJGMC and SGH, Pune-411001, Maharashtra, India.  
E-mail: sukanyakalekar30@gmail.com

#### AUTHOR DECLARATION:

- Financial or Other Competing Interests: None
- Was Ethics Committee Approval obtained for this study? Yes
- Was informed consent obtained from the subjects involved in the study? Yes
- For any images presented appropriate consent has been obtained from the subjects. NA

#### PLAGIARISM CHECKING METHODS: [Jain H et al.]

- Plagiarism X-checker: Apr 27, 2023
- Manual Googling: May 05, 2023
- iThenticate Software: May 20, 2023 (15%)

#### ETYMOLOGY: Author Origin

Date of Submission: **Mar 13, 2023**  
Date of Peer Review: **May 03, 2023**  
Date of Acceptance: **May 24, 2023**  
Date of Publishing: **Jun 01, 2023**