

Chasing Complications of Balloon Mitral Valvotomy

Shivakumar Bhairappa¹, Prakash Sadashivappa Surhonne¹,
Shankar Somanna¹, Rohit Chopra^{1*} and Cholenhally Nanjappa Manjunath¹

¹Department of Cardiology, Sri Jayadeva Institute of Cardiovascular Sciences and Research, Rajiv Gandhi University of Health Sciences, Jayanagar 9th Block, BG Road, Bangalore 560069, India.

Authors' contributions

This work was carried out in collaboration amongst all authors. All authors read and approved the final manuscript.

Article Information

DOI: 10.9734/CA/2015/18368

Editor(s):

(1) Shigenori Ito, Division of Cardiology, Nagoya City East Medical Center Nagoya, Japan.

Reviewers:

(1) Francesco Nappi, Department of Cardiac Surgery, Centre Cardiologique du Nord, France.

(2) Anonymous, University of Bari, Italy.

(3) Anonymous, Michigan State University, USA.

Complete Peer review History: <http://www.sciencedomain.org/review-history.php?iid=1198&id=26&aid=9713>

Case Study

Received 17th April 2015
Accepted 1st June 2015
Published 11th June 2015

ABSTRACT

Percutaneous balloon mitral valvotomy (BMV) done for mitral stenosis (MS) though largely improved nowadays can be followed by multiple and rare procedure related complications. We present an interesting case of a 45 year old male with symptomatic severe mitral stenosis of rheumatic origin. Ultimately, though he underwent a successful BMV it was ridden with multiple rare procedure related complications. Intra procedural perforation of left atrium with hemopericardium and pericardial tamponade occurred in the first attempt at BMV while rupture of BMV balloon, multiple clots in left atrium (LA) after the procedure and a large pericardial effusion occurred in the second albeit successful attempt. To the best of our knowledge this is the first case to report multiple LA clots post BMV.

Keywords: Left atrial clot; left atrial perforation; complications; tamponade.

1. INTRODUCTION

Rheumatic heart disease (RHD) though uncommon in the developed countries continues

to be highly prevalent in the developing nations. In the spectrum of rheumatic heart disease the most commonly affected valve is the mitral valve with Balloon Mitral Valvotomy (BMV) being the

*Corresponding author: E-mail: drrc2306@gmail.com;

most commonly done percutaneous procedure for mitral stenosis (MS) [1].

Over the last few decades the skill of the performing cardiologist as well as the techniques employed in BMV have improved vastly, thus greatly reducing the complications associated with it.

Yet no procedure is free of complications. Our case is one such where BMV done for symptomatic severe rheumatic MS was followed by multiple and rare complications.

2. CASE REPORT

A 45 year old Indian male presented with gradually progressive shortness of breath and exertional palpitations of 3 years duration. Over the last 3 years his shortness of breath and palpitations had worsened to NYHA class II. He had no other complaints and had an insignificant past medical and family history.

On examination he was found to have a regular heart rate of 70/min and blood pressure was 100/70 mm of Hg. Cardiac examination revealed a tapping apical impulse in the fifth intercostal space medial to mid clavicular line and on auscultation a loud first heart sound was heard at the apex. There was an opening snap (OS) followed by a long low pitched rumbling mid diastolic murmur with pre-systolic accentuation and a narrow A2- OS interval. Other systemic examination was within normal limits. An electrocardiogram done on arrival showed sinus rhythm with evidence of left atrial enlargement. Transthoracic echocardiogram (TTE) done showed severe valvular MS with valve area of 0.8 cm², enlarged left atrium (LA) (4.3 cm in parasternal long axis view), no mitral regurgitation with a Wilkin's score of 7. A diagnosis of RHD with severe MS was established. He was started on beta blockers and diuretics and a few days later he was admitted for BMV.

His pre procedural stay in the hospital was uneventful with routine haematology and biochemistry investigations being in normal range. A transesophageal echocardiogram (TEE) performed a day before the procedure showed no intracardiac thrombus (Fig. 1). While performing the procedure the next day, after interatrial septal puncture, on attempting to cross the mitral valve there occurred iatrogenic left atrial perforation with development of pericardial effusion and cardiac tamponade manifesting

clinically as hypotension. This called for an abandonment of the procedure and immediate pericardiocentesis was done with removal of 150 ml of bright red blood and a pericardial pigtail catheter was left in situ. He remained clinically stable after the pericardiocentesis with serial echocardiograms showing no further increase in pericardial fluid. After 2 days of observation the pigtail catheter was removed. He was closely observed and was discharged after 5 days with 2D echocardiogram showing mild pericardial effusion.

Two weeks later he was readmitted for a second attempt at BMV. TTE done before the procedure revealed mild pericardial effusion posterior to LA in parasternal long axis view (no increase in size compared to last echocardiogram) with no evidence of any clot in LA. He continued to be in sinus rhythm. The next day he was taken up for BMV and intra-procedurally 1500 units of unfractionated heparin (UFH) was administered initially at the time of sheath insertion and a second bolus of 3500 U (70 u/kg) was given after inter-atrial septal puncture. During the procedure, while inflating mitral valvotomy balloon to dilate the mitral valve the balloon failed to dilate proximally secondary to a tear at the proximal end of the inner layer of the balloon. Therefore this balloon was retrieved and the procedure was continued using a new balloon, with this there was a significant decline in left atrial pressure from 22 to 8 mm Hg after single inflation of 22 cubic centimetres of saline. Immediate post-procedural echocardiography done showed an increase in the mitral valve orifice area from 0.8 cm² to 1.7 cm² accompanied by a significant decline in gradient across the mitral valve with no suggestion of clinically significant iatrogenic mitral regurgitation or any clots in LA. He continued to remain clinically stable after the procedure.

Surprisingly, TTE performed next day showed mobile clots, one on the left atrial side of the interatrial septum and a second clot visualised near left atrial appendage (Figs. 2 and 3). A possibility of endothelial trauma leading to clot formation was considered and the patient was started on UFH and oral anticoagulation with Acenocoumarol. He was discharged after achievement of target prothrombin time (PT).

A week later he continued to remain unremarkable, his coagulation parameters showed a prothrombin time of 30.7 seconds with an international normalized ratio of 2.15. Review

TTE done showed resolution of both the clots. However, he had now developed a large pericardial effusion with no signs of pericardial tamponade (Fig. 4). There was no drop in his

haemoglobin levels, total leucocyte and platelet counts were normal and ESR was mildly elevated (39 mm/hr). His other laboratory parameters continued to remain normal.

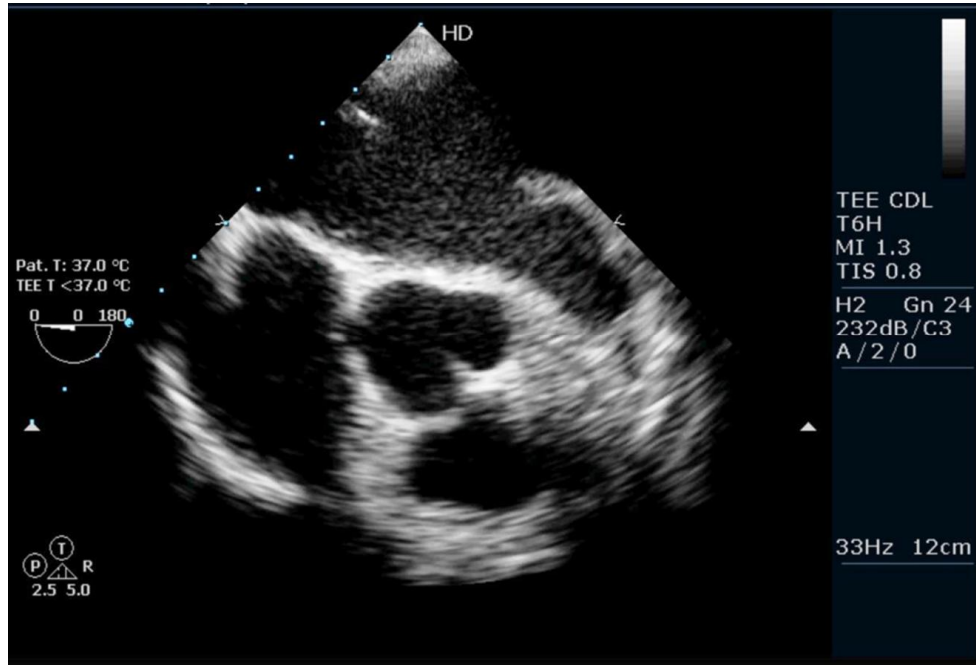


Fig. 1. Transesophageal imaging of the patient at zero degree showing grade I spontaneous ECHO contrast in LA with no clot in left atrium/atrial appendage

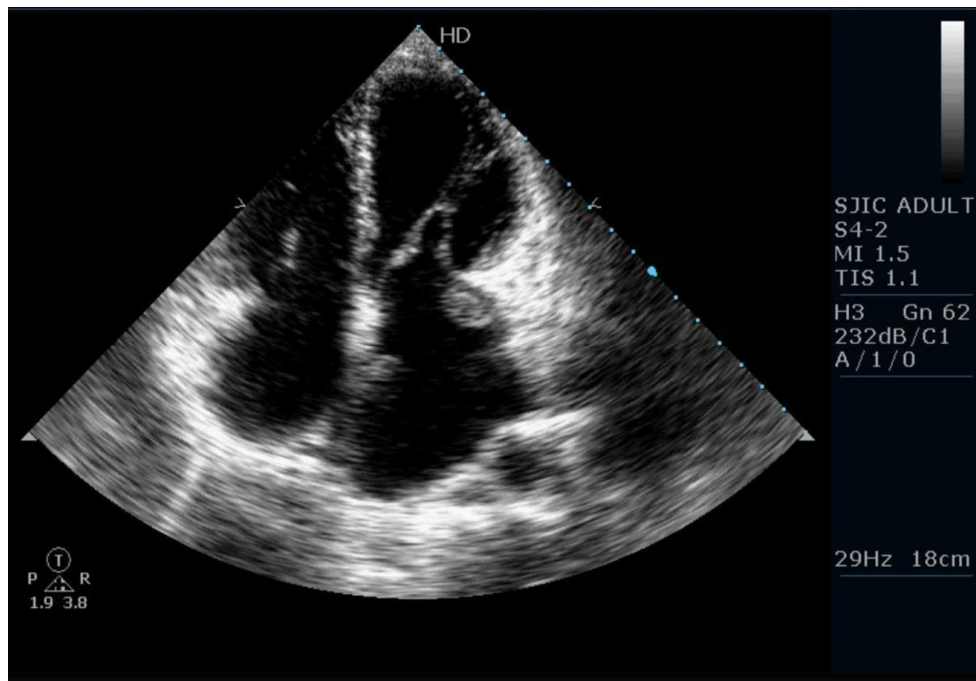


Fig. 2. Apical four chamber view showing clots, one on interatrial septum towards LA and second near left atrial appendage

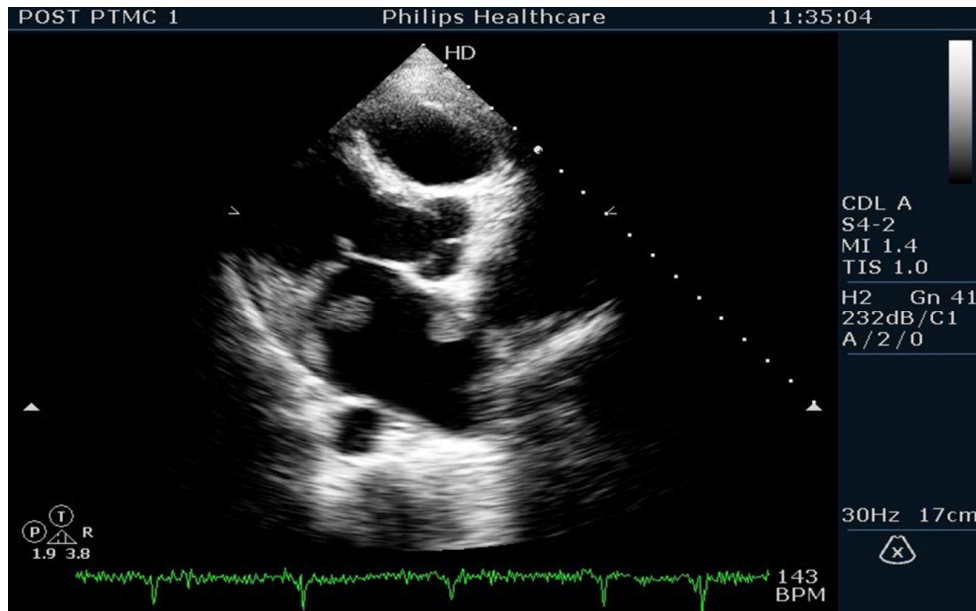


Fig. 3. Parasternal long axis view showing two distinct clots in left atrium

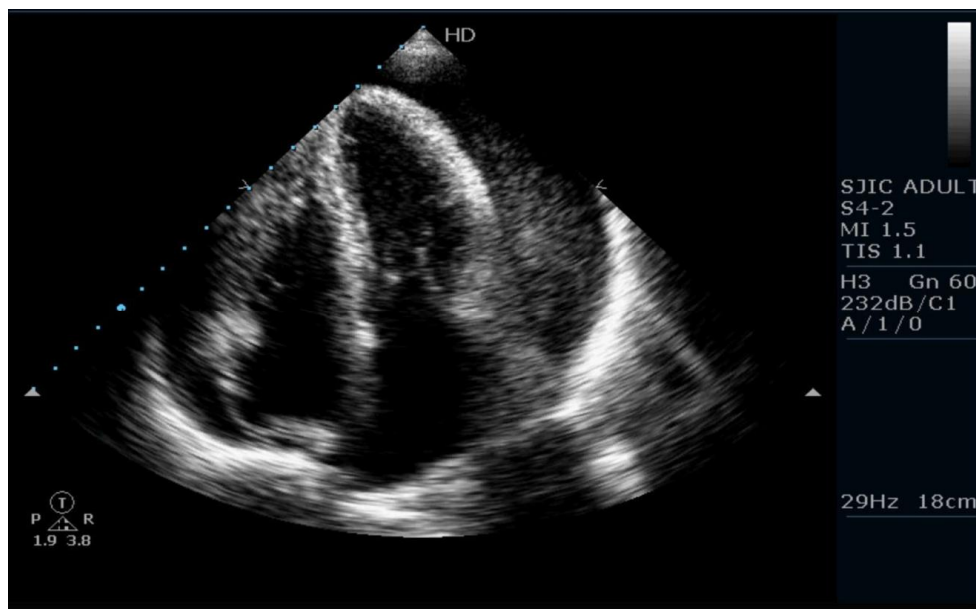


Fig. 4. Large pericardial effusion seen in apical four chamber view

In view of the large pericardial effusion he was readmitted, fresh frozen plasma was administered and Acenocoumarol was withheld. Pericardiocentesis was not considered as he was clinically stable with no hemodynamic compromise. Serial TTE done showed a decrease in pericardial effusion and hence a decision to discharge him was taken after one week of close observation. He was discharged

on beta blockers and Acenocoumarol was stopped. A month later he continued to be in good health and TTE performed showed mild pericardial effusion with no clot.

3. DISCUSSION

RHD continues to remain a major cardiac problem with a prevalence rate of 4.54/1000

persons in India [2]. With the advent of BMV, management options have dramatically improved. BMV has shown equal or better success rates and comparable restenosis rates in comparison to surgical mitral commissurotomy [3,4].

Most of the complications of BMV have been noted to occur during the procedure i.e., while performing interatrial septal puncture, manipulating BMV balloon in the LA or while inflating the balloon during commissurotomy [5]. Hemopericardium is the most common serious complication with an incidence of up to 2% [6]. Mortality with hemopericardium is rare with prompt recognition and immediate pericardial drainage either by pericardiocentesis or surgical pericardiotomy. In our case LA rupture was recognized and managed early with pericardiocentesis.

Rupture of valvotomy balloons has been described and is more common with used balloons [7,8]. Clot at interatrial septum following BMV is an extremely rare occurrence with very few case reports having been described in literature [9,10]. To the best of our knowledge, our case is the first case to describe formation of clot at multiple sites in LA namely at the LA side of interatrial septum and near LA appendage, possibly due to endothelial injury sustained while manipulating the hardware in LA. In our case patient developed multiple clots in LA despite anticoagulating the patient during the procedure. As the procedure time was short (around 20 minutes) activated clotting time (ACT) was not monitored.

The development of pericardial effusion 10 days after the procedure could be due to an incompletely healed LA rent which could have led to the development of a gradually increasing pericardial effusion after starting the patient on anticoagulation.

4. CONCLUSION

Left atrial perforation during BMV is a potentially lethal complication. Proper technique of septal puncture and gentle manipulation of hardware in LA can prevent this complication. Patients developing LA perforation should be followed up closely and repeat attempt, after failed initial procedure, should be undertaken only after allowing the rent in LA to heal adequately. Intracardiac clot formation after the procedure, although rare, may still occur despite

anticoagulating with heparin during the procedure. From our experience we suggest that ACT should always be checked and maintained adequately in all patients undergoing BMV.

CONSENT

It is not applicable.

ETHICAL APPROVAL

It is not applicable.

ACKNOWLEDGMENTS

This case has not been presented in any journal or scientific meeting. There were no external funding sources for this case reporting.

COMPETING INTERESTS

Authors have declared that no competing interests exist.

REFERENCES

1. WHO study group, Rheumatic fever and rheumatic heart disease. WHO technical report series No. 764. Geneva: World health organization; 1988.
2. Ahemad MZ JP, Narayanan SN. Rheumatic chorea in children: A study of prevalence of clinical and echocardiographic valvular involvement. *Indian Heart J.* 1999;51:694.
3. Turi ZG, Reyes VP, Raju BS, Raju AR, Kumar DN, Rajagopal P, Sathyanarayana PV, Rao DP, Srinath K, Peters P. Percutaneous balloon versus surgical closed commissurotomy for mitral stenosis: A prospective, randomized trial. *Circulation.* 1991;83:1179–1185.
4. Arora R, Nair M, Kalra GS, Nigam M, Khalilullah M. Immediate and long-term results of balloon and surgical closed mitral valvotomy: A randomized comparative study. *Am Heart J.* 1993;125:1091-1094.
5. Nobuyoshi M, Hamasaki N, Kimura T, Nosaka H, Yokoi H, Yasumoto H, Horiuchi H, Nakashima H, Shindo T, Mori T. Indications, complications, and short-term clinical outcome of percutaneous transvenous mitral commissurotomy. *Circulation.* 1989;80:782-792.
6. Martinez-rios MA, Tovar S, Luna J, Eid-Lidt G. Percutaneous mitral commissurotomy. *Cardiol Rev.* 1999;7:108-116.

7. Schilling JR, Francis CM, Shaw TRD, Norell MS. Inoue balloon rupture during dilatation of calcified mitral valves. *Br Heart*. 1995;72:390.
8. Singla V, Patra S, Patil S, Ramalingam R. Accura balloon rupture during percutaneous trans-septal mitral commissurotomy: A rare and potentially fatal complication. *BMJ Case Reports*; 2013. DOI:10.1136/bcr-2013-009819.
9. Raman VG, Ramachandran P, Kansal N. An unusual complication of cardiac catheterisation during BMV. *BMJ Case Rep* 2011; 2011.
10. Yuksel IO, Kucukseymen S, Cagirci G, Arslan S. A case of percutaneous mitral balloon valvuloplasty complicated by pericardial effusion and thrombus formation on the interatrial septum. *Turk Kardiyol Dern Ars*. 2014;42(8):747-50 (in Turkish).

© 2015 Bhairappa et al.; This is an Open Access article distributed under the terms of the Creative Commons Attribution License (<http://creativecommons.org/licenses/by/4.0>), which permits unrestricted use, distribution, and reproduction in any medium, provided the original work is properly cited.

Peer-review history:

The peer review history for this paper can be accessed here:
<http://www.sciencedomain.org/review-history.php?iid=1198&id=26&aid=9713>