



## **Fatal Fulminant Hepatic Failure in a Case of Zinc Phosphide Poisoning: A Case Report**

**Akhilesh Annadatha<sup>a\*</sup>, Sourya Acharya<sup>a†</sup>, Dhruv Talwar<sup>a#</sup>, Sunil Kumar<sup>a‡</sup>  
and Anuj Varma<sup>a‡</sup>**

<sup>a</sup> Department of Medicine, Jawaharlal Nehru Medical College, Sawangi, Wardha, India.

### **Authors' contributions**

*This work was carried out in collaboration among all authors. All authors read and approved the final manuscript.*

### **Article Information**

DOI: 10.9734/JPRI/2021/v33i54B33760

Editor(s):

(1) Dr. Ana Cláudia Coelho, University of Trás-os-Montes and Alto Douro, Portugal.

Reviewers:

(1) Hyder Mirghani, University of Tabuk, Saudi Arabia.

(2) Farhanul Huda, All India Institute of Medical Sciences Rishikesh, India.

Complete Peer review History, details of the editor(s), Reviewers and additional Reviewers are available here:

<https://www.sdiarticle5.com/review-history/78118>

**Case Study**

**Received 02 October 2021**  
**Accepted 06 December 2021**  
**Published 11 December 2021**

### **ABSTRACT**

Rodenticide is the term given for the compounds that are used in the killing of rats. The commonest compounds that are available as rodenticides are Aluminum phosphide, Zinc Phosphide, Yellow Phosphorus and Coumarins. Due to their easy availability in the general stores, these also have been used as a source of inflicting self-harm by the patients in order to commit suicide. Most of the patients escape the poisonous side effects with a mild course, but some cases progress to a state of Acute liver failure or fulminant liver failure. Due to the broad range of symptoms that can occur with the compounds, it is important to discuss the course of progression of symptoms from mild to severe in order to understand the treatment protocols to treat the patient appropriately. Some patients progress to such a severe form of symptoms that there is an urgent indication of liver transplantation. Here we report a case of rodenticide poisoning in a young female which started off with a mild course and ultimately progressed to fulminant liver failure leading to a fatal outcome.

**Keywords:** Rodenticide; fatal outcome; Fulminant hepatic failure.

# Resident;

† Professor and Head;

‡ Professor;

\*Corresponding author: E-mail: [achyutakhilesh@gmail.com](mailto:achyutakhilesh@gmail.com);

## 1. INTRODUCTION

Suicide methods or Deliberate Self Harm (DSH) is becoming a global burden. With easy access to various kinds of poisons, the rates of DSH have gone up exponentially in the past decade. In the Indian subcontinent, various compounds are used for DSH. Insecticides, pesticides and other lethal compounds ingestion are the commonest causes of DSH. Rodenticide is the term used for the agents that are used in eradicating the rats and mice species. The use of Rodenticides as a way of inflicting DSH has gained prominence in the recent past. Rodenticide use has increased due to low cost, easy availability, ease of access to the compound [1]. Most of the cases are underreported. In a study done in the South Karnataka region of India, the incidence of rodenticide poisoning in all cases of acute poisoning was found out to be 7.9% [2]. These statistics show the prominence of rodenticide as a mode of poisoning. As mentioned, the different compounds that act as rodenticides have separate toxidromes and outcomes when consumed [3]. The coumarins belong to a class of anticoagulants, the compounds zinc and aluminum phosphide belongs to the group of phosphates. Initially, it was noted that coumarins contributed to around 80-90% of rodenticide poisoning cases, but recently the cases of phosphate compounds poisoning have risen in the united states [4]. But the statistics in India show otherwise. Major instances have shown phosphide compounds as the predominant chemicals of rodenticide poisoning. Out of the phosphide compounds, zinc phosphide poisoning was seen in a majority of the cases. Out of the above compounds, Aluminium phosphide showed the maximum mortality when consumed [5]. Phosphine is the compound that produces the side effects of the rat kill poison Zinc phosphide. Zinc phosphide has a cellular and mitochondrial action which results in the inactivation of certain enzymes like Lactoperoxidase, Cytochrome C oxidase to name a few which ultimately results in end organ damage. Phosphine is known to be a protoplasmic poison that inhibits different enzymes and also the synthesis of proteins.

## 2. CASE PRESENTATION

A 25-year-old female presented to the hospital with the complaints of multiple episodes of vomiting, pain in the right upper quadrant since 3 days. The patient had a history of consumption of

rat kill poison (Zinc Phosphide) of quantity unknown and post consumption had complaints of 2 episodes of vomiting and was taken to a local hospital where she was conservatively treated starting with gastric lavage, injection Vitamin K, and other supportive measures. The patient was feeling better after the initiation of treatment where her symptoms subsided. After 3 days, the patient had complaints of multiple episodes of vomiting, pain in the right upper quadrant of abdomen, multiple episodes of fever and was referred to our hospital for further management.

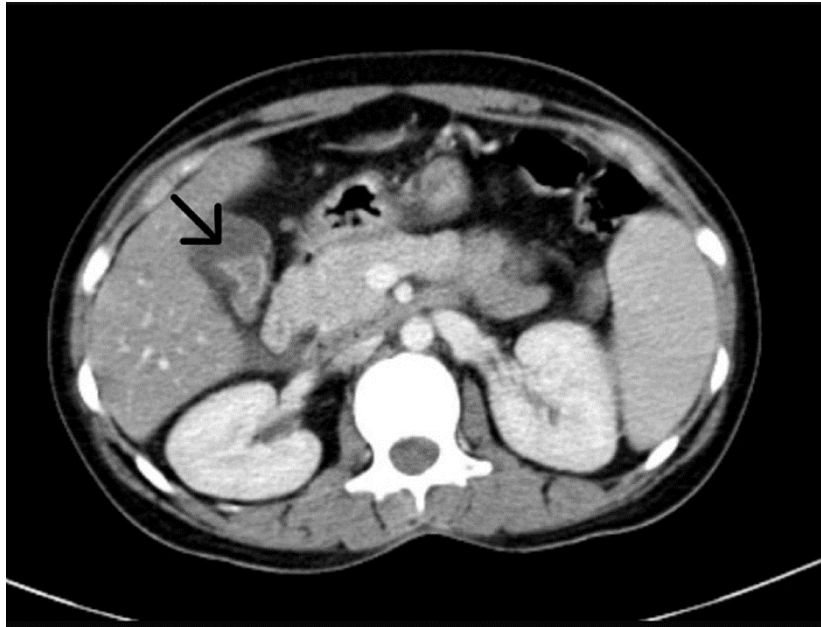
On examination, her general condition was poor, was febrile on touch (102oF), CVS - S1 S2 heard, R/S - B/L Clear, P/A - Soft, diffuse tenderness present, guarding present, rigidity present, Liver was not palpable, CNS examination revealed the presence of flapping tremors and her plantars were extensor bilaterally. Her reports showed ALT of 871 IU and AST of 2141 IU, Total bilirubin was 2.8 mg/dl of which conjugated bilirubin was 1.8 mg/dl and unconjugated was 1.0 mg/dl. Her coagulation profile showed a prothrombin time of 40.8 secs (control - 11.9 sec) with an INR of 3.60.

She was started on Injection Glutathione 600 mg iv bd, L-ornithine L-Aspartate, Ursodeoxycholic acid, was given Inj Vitamin K 10 mg and was transfused with 5 units of Fresh Frozen Plasma and was put on other supportive medications. She was also given continuous infusions of N-Acetyl Cysteine in the dosage of 150 mg in the first hour followed by 50 mg/kg/hr for the next 4 hours followed by 100 mg/kg/hr for the next 15 hours. Despite starting of appropriate treatment, her vital parameters and lab reports did not show any considerable improvement. Her ALT and AST levels reached 1681 and 5477 IU respectively. Her INR rose to 4.02 and was eventually 7.02 despite repeated transfusions of fresh frozen plasma. She was diagnosed as a case of Fulminant Hepatic Failure secondary to rat kill poisoning and with such rapid deterioration of her liver function, the relatives were explained the need of needing an immediate liver transplant in the patient. With the financial constraints that the relatives had, they had given consent for continuing medical management although poor outcome was explained. Despite rat kill poisoning being the etiology, the other causes of fulminant hepatic failure like Dengue, Malaria, Leptospirosis, Hepatitis B, Hepatitis A were ruled out. NS1Ag and IgM and IgG for Dengue were negative,

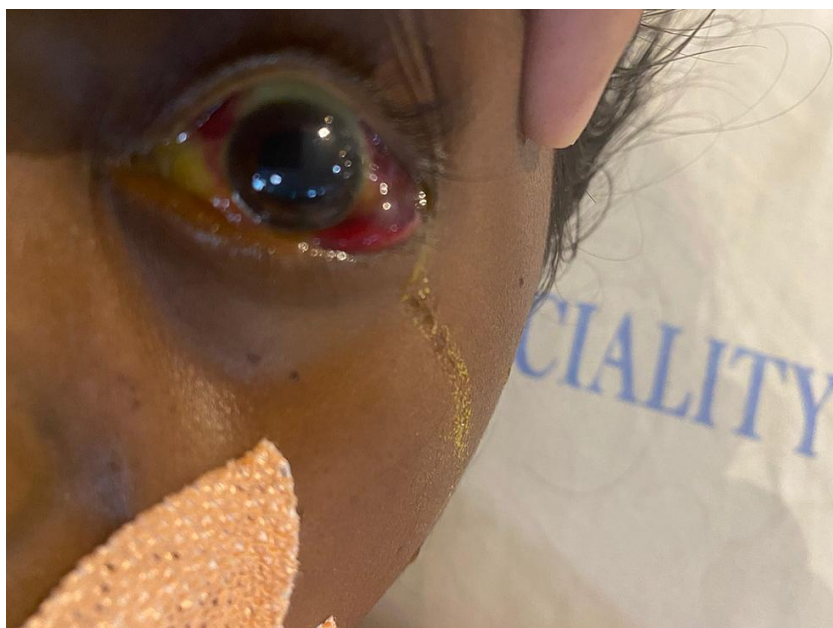
Parachek was negative, serologies for Leptospira, HbsAg and Hep A serologies were negative.

Contrast-Enhanced Computed Tomography of Abdomen was done which showed decreased parenchymal density of liver showing homogenous post contrast enhancement with severe gall bladder wall edema suggestive of

Hepatitis (Fig. 1). Patient gradually showed an increase in bilirubin levels which manifested as Icterus. She also developed Sub Conjunctival haemorrhage (Fig. 2). Patient gradually deteriorated and had to be put on ventilator support and could not be weaned off from the same. Patient eventually developed multi organ failure and succumbed to the same two days following admission.



**Fig. 1. Contrast-enhanced computed tomography of the abdomen showing decreased parenchymal density of liver with homogenous post-contrast enhancement**



**Fig. 2. Showing conjunctival haemorrhage**

### 3. DISCUSSION

Rat kill poisoning is extremely dangerous which can progress to fulminant hepatic failure in due course. The course can be mild with symptoms of nausea, vomiting to life-threatening symptoms of coagulopathy. With no definitive treatment available for the poison, and Vitamin K is the closest antidote available, early recognition of the toxic compound and aggressive management is the key to treating such patients. Fulminant Hepatic Failure can only be definitively treated by Liver transplantation. N-acetyl cysteine, L-Ornithine L-Aspartate, Glutathione, Ursodeoxycholic acid has a limited role in treating fulminant hepatic failure in rat kill poisoning cases due to the aggressive course of the disease [6-7]. Liver transplantation is the definitive treatment in these cases with no major contraindications except the presence of a neurological dysfunction secondary to liver failure in rodenticide poisoning [8]. The poison that usually has gastrointestinal and cardiovascular side effects commonly has the rarer side effect of Acute Fulminant Hepatic failure also. Although the initial presentation may deceive the treating physician with the normalcy of liver enzymes should be closely monitored for the next 3-4 days for the manifestation of latent liver failure [9-10]. Zinc Phosphide is a highly effective rodenticide that results in the disruption of cellular as well as mitochondrial systems. This occurs due to the dysfunction of cytochrome C oxidase, as well as lactoperoxidase due to free radical generation, abnormalities of electrolytes and changes witnessed in various essential enzymes of the liver or other organs like the kidney and lung, resulting in organs toxicity such as hepatotoxicity [11]. Phosphide from zinc phosphide which comes in contact with water or acid results in the formation of a highly toxic compound which is phosphine gas. This phosphine gas inhibits oxygen consumption at the cellular level due to its direct effect on mitochondria as well as reducing cytochrome oxidase activity [12]. N-Acetyl Cysteine is an essential antioxidant as well as an agent which is cytoprotective which increases glutathione inside the cell. It counteracts the action of reactive oxygen radicals by either repairing the damage done by free radicals or by carrying out scavenging action over these oxygen radicals which otherwise lead to cell damage and death [11]. This explains the rationale of using n-acetyl cysteine in our case.

Our patient was also managed with intravenous vitamin K and other supportive measures such as fresh frozen plasma to correct the coagulopathy induced by fulminant hepatic failure.

Careful clinical examination and progressive monitoring of coagulation profile, liver function tests are key to treating any rat kill poisoning case. It is important for the clinicians to remember that rat kill or zinc phosphide poisoning has the potential to cause progression of liver failure which is usually refractory to medical management with the ability to result in a fatal outcome such as in our case. Hence, it is important for the treating physicians to keep a close eye for noting deterioration in such cases of zinc phosphide as such cases can take a dangerous detour at any point of time making it difficult to prevent mortality. In times where poisoning with rat kill is rampant, the delirious effects and the complications that the poison can cause is important and when complications like Sub conjunctival haemorrhage not regularly encountered, we have felt the need to report this case to give a reminder to the practicing physicians, the magnitude of the effects that can be seen.

### 4. CONCLUSIONS

We conclude that Zinc Phosphide poisoning is a dangerous and potentially lethal condition that can result in mortality even in a young patient by causing fulminant hepatic failure. The treating physicians should therefore monitor such patients carefully to detect a downhill course as early as possible to prevent possible fatal complications in an otherwise benign-looking course of rat kill poisoning

### CONSENT

As per international standard or university standard, patient's written consent has been collected and preserved by the author(s).

### ETHICAL APPROVAL

As per international standard or university standard written ethical approval has been collected and preserved by the author(s).

### COMPETING INTERESTS

Authors have declared that no competing interests exist.

## REFERENCES

1. Ramesha KN, Rao KB, Kumar GS: Pattern and outcome of acute poisoning cases in a tertiary care hospital in Karnataka, India. Indian J Crit Care Med. 2009;13:152-5. DOI:10.4103/0972-5229.58541
2. Jayakaran JJ, Abhilash KP. Rodenticide poisoning: Literature review and management. Curr Med Issu. 2019 17: DOI:10.4103/cmi.cmi\_54\_1
3. Kishore PV, Palaian S, Prabhu M, Mishra P: Consumption of rodenticides by humans J Inst Med. (Consumption of rodenticides by humans | Journal of Institute of Medicine Nepal. 2007;29:50-2. Available:https://www.nepjol.info/index.php/JIOM/article/view/1197/0.
4. Eisemann JD, Petersen BE. Human Poisonings and Rodenticides: Evaluation of Incidents Reported to the American Association of Poison Control Centers. USDA National Wildlife Research Center - Staff Publications; 2002481. Available:https://digitalcommons.unl.edu/cgi/viewcontent.cgi?article=1476&context=icwdm\_usdanwrc.
5. Suneetha DK, Inbanathan J, Kannoth S, Reshma PK, Shashank MS: Profile of rat killer poisoning cases in a tertiary care hospital at Mysore. Int J Sci Stud. 2016;3: 264-7. DOI:10.17354/ijss/2016/162
6. Kharkongor M, Mishra A, Ninan KF, Iyadurai R. Early use of intravenous N-acetylcysteine in treatment of acute yellow phosphorus poisoning. Curr Med Issues. 2017;15(2):136. DOI:10.4103/0973-4651.206530
7. Nalabothu M, Monigari N, Acharya R: Clinical Profile and outcomes of rodenticide poisoning in tertiary care hospital. Int J Sci Res Pub (Clinical Profile. 2015;5(8): 1-2. DOI:10.18203/2320-6012.ijrms20163811
8. Reddy MS, Rajakumar A, Mathew JS: Liver Transplantation Society of India guidelines for the management of acute liver injury secondary to yellow phosphorus-containing rodenticide poisoning using the modified Delphi technique of consensus development. J Clin Exp Hepatol. 2021;11(4):475-83. DOI:10.1016/j.jceh.2020.09.011
9. Acharya S, Shukla S, Raisinghani N: Successful management of rodenticide induced acute liver failure in a patient. Toxicol Int. 2014;21:10.4103/0971-6580.155394
10. Rasheed A, Acharya S, Shukla S: Case report: Yellow phosphorus induced acute fulminant hepatitis and acute kidney injury in a male. Int J Med Sci. 2018; 5. Available:10.14445/23939117/IJMS-V5I11P101
11. Oghabian Z, Afshar A, Rahimi HR: Hepatotoxicity due to zinc phosphide poisoning in two patients: role of N-acetylcysteine. Clin Case Rep. 2016;768-772. DOI:10.1002/ccr3.618
12. Omid Mehrpour, Dan Keyler & Shahin Shadnia. Comment on Aluminum and zinc phosphide poisoning. Clinical Toxicology. 2009;47;8:838-839. DOI:10.1080/15563650903203684

© 2021 Annadatha et al.; This is an Open Access article distributed under the terms of the Creative Commons Attribution License (<http://creativecommons.org/licenses/by/4.0>), which permits unrestricted use, distribution, and reproduction in any medium, provided the original work is properly cited.

*Peer-review history:*  
*The peer review history for this paper can be accessed here:*  
<https://www.sdiarticle5.com/review-history/78118>